

Retrospective Clinical Comparison of Hemangioma Treatment by Flashlamp-Pumped (585 nm) and Frequency-Doubled Nd:YAG (532 nm) Lasers

Christian Raulin, MD,* and Bärbel Greve, MD

Practice for Dermatology, Phlebology, and Allergology, Laserklinik Karlsruhe, Germany

Background and Objective: Laser therapy using the flashlamp-pumped pulsed dye laser (FPDL), along with contact cryotherapy, has proven to be an effective method with few side effects in the early treatment of superficial hemangiomas in infancy. The long-pulsed frequency-doubled Nd:YAG laser (VersaPulse®) is a new kind of laser whose efficacy and safety we examined in direct comparison with the FPDL.

Study Design/Materials and Methods: In a retrospective comparative study, we treated 50 infants with a total of 62 superficial hemangiomas. A total of 29 hemangiomas were treated with the FPDL (wavelength 585 nm, impulse duration 0.3–0.45 msec), 33 with the VersaPulse® (wavelength 532 nm, impulse duration 1–50 msec).

Results: With an average of 3.0 and 2.6 treatments (FPDL/VersaPulse® respectively), a cessation of growth or regressive tendency could be achieved in 93% and 70% of the hemangiomas, respectively. Complete regression occurred in 41% (FPDL) or 30% (VersaPulse®). Only in 7% (FPDL) or 18% (VersaPulse®) was there progression despite laser therapy. The side effect rates of both laser systems were low.

Conclusion: The FPDL has proven to be the slightly more effective treatment method in comparison and, therefore, remains the therapy of choice for the initial treatment. If parents wish to pursue further treatment in the regression phase of hemangiomas to optimize the cosmetic appearance, we recommend the VersaPulse® due to its low rates of side effects and painfulness. *Lasers Surg. Med.* 28:40–43, 2001. © 2001 Wiley-Liss, Inc.

Key words: hemangiomas; flashlamp-pumped pulsed dye laser; long-pulsed frequency-doubled Nd:YAG laser

INTRODUCTION

The early treatment of infant hemangiomas, especially in problematic anatomic sites, has been gaining increasing acceptance and establishing itself as common practice in the past few years. In addition to contact cryotherapy, laser therapy plays a decisive role in the process [1–4]. To date, the FPDL has been considered the most effective method with the fewest side effects for initial, flat infant hemangiomas [3–9].

The development of lasers with continually increasing impulse duration and higher fluences has aroused great

interest. To a great extent, the epidermis is protected from thermal damage by the use of cooling devices during the laser process. The VersaPulse® with impulse lengths up to 50 msec and fluences up to 40 J/cm² is an example of this new generation of lasers. Due to a wavelength of 532 nm, which comes close to the absorption maximum of oxygenated hemoglobin, it targets small dermal vessels exactly as the FPDL does. In the treatment of superficial vascular skin lesions such as port wine stains and essential and leg telangiectasias, this laser has already proven itself to be an effective therapy method [10–15]. To compare both lasers directly, we examined and treated 50 infants with a total of 62 superficial infant hemangiomas over a period of 12 months.

PATIENTS AND METHOD

A total of 62 hemangiomas in 50 healthy infants (33 female, 17 male) were treated either with the FPDL (Photo Genica V, wavelength 585 nm, Cynosure, Inc.) or with the long-pulsed, frequency-doubled Nd:YAG laser (VersaPulse®, wavelength 532 nm, Coherent, Palo Alto, CA).

The VersaPulse® has an impulse diameter of 2 to 10 mm. The impulse duration can be variably set between 2 and 50 msec. Depending on the combination of impulse duration and diameter fluences of 0.6 to 40 J/cm² are achieved. We determined that a diameter of 5 mm, a fluence of 20 J/cm², and an impulse duration of 50 msec were ideal treatment parameters for hemangiomas. Higher fluences, which can only be achieved by decreasing the diameter with this device, lead to preliminary poor effects, possibly due to the reduced penetration depth, and an increased rate of side effects (crusting, blisters).

The main areas of the hemangiomas were the head and neck region (41%), followed by the trunk (31%), arms and legs (21%), and the anogenital area (7%). All patients had Fitzpatrick skin types I–II.

The only hemangiomas included in this study were superficial ones with a maximum surface area of up to 5 cm²,

*Correspondence to: Christian Raulin, MD, Laserklinik Karlsruhe, Kaiserstr. 104, 76133 Karlsruhe, Germany.
E-mail: www.raulin.de

Accepted 17 July 2000

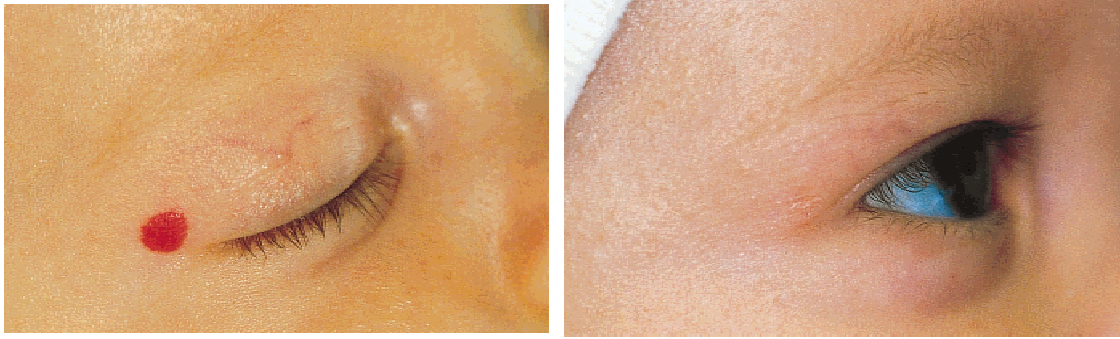


Fig. 1. **A:** A 2-month-old infant with a superficial hemangioma near the right eye. **B:** Complete removal as shown 10 months after the third treatment with the flashlamp-pumped pulsed dye laser (FPDL).

a maximum thickness of up to 1.5 mm, and a recognizable growth tendency. Before treatment, the parents were thoroughly informed about how hemangiomas grow in phases and the possible side effects of laser therapy (blisters, crusts, swelling, erythema, scars, and, in the case of dye laser therapy, blue maculae, which could persist for up to 10 days). We prescribed iodine ointment (Bettaisona®) for exudative reactions and severe crusting.

Further treatment was to follow immediately in the event of emerging complications or a fast growth tendency; otherwise, it took place between 4–8 weeks after the last treatment. A final check was planned for 12 months after the first treatment.

The hemangiomas were photodocumented before each individual examination or treatment, as well as on the day of the last check (12 months after the first treatment). The regression rates were evaluated according to a scale of 0–100% by two independent doctors, as well as by the parents. Photos were taken with a Canon EOS100, by using Agfa Ctx100 film. A statistical analysis of the test results was not performed because of the small number of participants.

RESULTS

In the FPDL group, a total of 29 hemangiomas were treated (Fig. 1); in the VersaPulse® group, 33 hemangiomas were treated (Fig. 2). The average size was 1.8 cm² and 1.3 cm² (FPDL and VersaPulse®, respectively). For treatment with the FPDL, an impulse diameter of 7 mm and fluences of 5.3–6.8 J/cm² were applied. For the VersaPulse®, an impulse diameter of 5 mm, an impulse duration of 50 msec, and a fluence of 20 J/cm² were used.

In the group that was treated with the FPDL, a regression could be achieved in 24 hemangiomas (83%) after an average of 3.0 treatments. Of these, 37% showed 100% regression, 54% regressed between 70–99%, and for 8% the regression rate was below 70%. Only two hemangiomas (7%) showed a growth tendency despite treatment.

The hemangiomas of the comparative group required an average of 2.6 treatments. A regression of the hemangiomas occurred in 23 cases (70%): 100% regression was achieved in 21%, 70–99% regression was achieved in 39%,

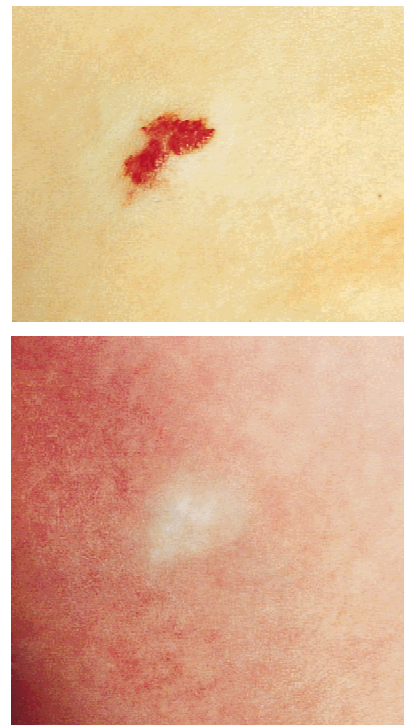


Fig. 2. **A:** A 4-month-old infant with a superficial hemangioma under the left shoulder. **B:** Complete removal with slight hypopigmentation and apparent atrophy 11 months after the third treatment with the long-pulsed Nd:YAG laser (VersaPulse®).

and regression under 70% occurred in only 9% of the cases. In five hemangiomas (18%), growth could not be prevented; 6% remained unchanged. In two infants, no follow-up was possible because there were no repeat visits after the initial treatment.

Postoperative, transient swelling was present in 100% of the treated hemangiomas; in the Nd:YAG group, this was conspicuously more pronounced and lasted longer (up to 3 days). In comparison, in the dye laser group, crusts and blisters (76% vs. 24%), transient hyperpigmentation (20% vs. 0%) and the appearance of purpura (100% vs.

TABLE 1. Results

Parameter	Dye laser (%)	Nd:YAG laser	
Number of patients	25	25	
Number of hemangiomas		29	33
Average number of treatments		3.0	2.6
Regression of hemangiomas (total)		27 (93)	23 (70)
100%	11 (41)	7 (30)	
70–99%	14 (52)	13 (57)	
<70%	2 (7)	3 (13)	
Growth	2 (7)	6 (18)	
No change	—	2 (6)	
No further treatment	—	2 (6)	
Side effects (per hemangioma, some multiple appearance)			
Purpura	25 (100)	5 (20)	
Crusts and blisters	1 (76)	8 (24)	
Swelling	25 (100)	25 (100)	
Hypopigmentation	3 (10)	2 (6)	
Hyperpigmentation	6 (20)	—	
Atrophic scars	1 (3.4)	1 (3)	

20%) predominated. In 3.4% and 3% (FPDL and VersaPulse®, respectively), atrophic scarring occurred. A summary of the results is shown in Table 1.

DISCUSSION

In the past few years, the early treatment of hemangiomas, especially in problematic anatomic sites, has been gaining increasing acceptance. Due to unpredictable growth of hemangioma and because effective treatment methods with few side effects exist, it may not always be prudent to wait for spontaneous regression. For superficial hemangiomas, the FPDL in particular has proven itself in numerous studies, along with contact cryotherapy [1–4,7–9]. Hemangiomas with subcutaneous portions do not react as well to laser therapy or contact cryotherapy [1–2,5,6–9].

Due to the two principles of “selective photothermolysis” [16] and “thermal relaxation time,” only lasers with extremely short impulse times have been used and scientifically researched for many years. Fiskerstrand et al. [17] and van Gemert et al. [18] were the first who proposed that the cause of dissatisfactory results in the treatment of port wine stains could be traced back to the use of an impulse length of the FPDL that might have been too brief (0.45 msec). This theory has been confirmed by the research done by Dierickx et al. who ascertained by way of example that vessels 30–150 μm in size, as they were histologically measured in port wine stains, require an impulse length of 1–10 msec for efficient coagulation [19].

The VersaPulse® is a new development that meets the above-mentioned requirements. With a wavelength of 532 nm, the VersaPulse® is close to one of the absorption maximums of oxygenated hemoglobin and, therefore, like the FPDL, targets small dermal vessels according to the principle of selective photothermolysis. Due to its long impulse duration, high fluences and its higher melanin absorption than at 585 nm, it nevertheless requires additional super-

ficial cooling to prevent any significant thermal damage to the upper dermis. For this purpose, a so-called “chilled tip™” has been developed, which is continually guided over the skin during the laser process.

Positive results have been described to date for the treatment of port wine stains and essential and leg telangiectasias with this laser type [10–15]. In this study, the side effect rate of the VersaPulse® is evaluated as being low. It is noteworthy that the laser impulse of the VersaPulse® is perceived as being less painful [12,15]. A total of 87% of the female subjects stated that the pain was “slight” in a study by Bethge and Stadler [12]. West and Alster researched the pain intensity in the FPDL compared with the VersaPulse® [15]. On a scale of 1–10, patients evaluated the painfulness at 5.6 for the FPDL, and 3.9 for the long-pulsed Nd:YAG laser. A further advantage of the VersaPulse® is that purple maculae did not occur for the most part, as is typical after treatment with the FPDL [12,15]. Despite their transient character, they are often considered extremely cosmetically bothersome by the patients. Intravasal coagulated blood is histologically regarded as a correlate of purple maculae. It remains unexplained why these do not appear after treatment with the VersaPulse®, although Adrian et al. also report on thrombogenic vascular occlusion [10–12,15].

Because of the mode of action and the good results of the above-mentioned studies, the objective was to examine the efficacy and side effect rate of the long-pulsed, frequency-doubled Nd:YAG laser for the treatment of superficial hemangiomas in direct comparison with the FPDL. The results presented indicate that both procedures are safe and effective treatment procedures with few side effects. With an average of 3.0 and 2.6 treatments (FPDL/VersaPulse®), a cessation of growth or a regressive tendency could be achieved in 93% and 70% of the hemangiomas. Complete regression occurred in 41% (FPDL) and 30% (VersaPulse®). Growth could not be stopped in only 7% (FPDL) and 18% (VersaPulse®). Due to higher penetration depth and lower melanin absorption, however, a clearer superiority of the dye laser would have been expected.

The side effect rates of both laser systems were low; the long-pulsed Nd:YAG laser proved to cause fewer side effects. Both hyper- and hypopigmentation were of a transient nature and were not detectable anymore after an average of 3 months. The appearance of small atrophic scars, which occurred in one case in each group, should not be solely regarded as a side effect of laser therapy, but must also be discussed as scarring residue of the hemangiomas. However, based on experience, these are also transient in nature and regress over the course of the first years.

Our results coincide well with the published studies. Garden et al. [6] observed an average lightening of 93.9% in superficial hemangiomas after 4 treatments with the FPDL; Hohenleutner et al. [8] achieved an average regression rate of 63–67% after multiple treatments. Hellwig and Raulin [7] and Ashinoff and Geronemus [5] report

similar good results. The side effect rates were extremely low in all studies. All authors correspondingly report that growth or the development of subcutaneous portions cannot be stopped by laser therapy with the FPDL in all cases [3–9]. The low penetration depth of the VersaPulse® limits its indication spectrum, as is the case with the FPDL.

In conclusion, the FPDL and the VersaPulse® are effective treatment methods with few side effects for superficial hemangiomas in infancy. Nevertheless, we recommend the FPDL as the first choice of treatment due to its slightly higher rates of regressions. The VersaPulse®, which is distinguished by its low side effect rate and the minor pain it causes, is a good alternative if parents wish to improve their child's cosmetic appearance in the regression phase.

REFERENCES

1. Castro-Ron G. Cryosurgery of angiomas and birth defects. In: Zacarian SA, editor. Cryosurgery for skin cancer and cutaneous disorders. St. Louis: Mosby; 1995. p 77.
2. Cremer HJ, Djawari D. Frühtherapie der kutanen Hämangiome mit der Kontaktkryochirurgie. *Chir Prax* 1995;49:295–312.
3. Frieden IJ. Which hemangiomas to treat - and how? *Arch Dermatol* 1997;133:1593–1595.
4. Frieden IJ, Eichenfield LF, Esterly NB, Geronemus R, Malloy SB. Guidelines for care of hemangiomas in infancy. *Am Acad Dermatol* 1997;37:631–637.
5. Ashinoff R, Geronemus RG. Capillary hemangiomas and treatment with the flashlamp-pumped pulsed dye laser. *Arch Dermatol* 1991;127:202–205.
6. Garden JM, Bakus AD, Paller AS. Treatment of cutaneous hemangiomas by the flashlamp-pumped pulsed dye laser: prospective analysis. *J Pediatr* 1992;120:555–560.
7. Hellwig S, Raulin C. Die Behandlung von Hämangiomen im Säuglings- und Kindesalter mit dem gepulsten Farbstofflaser. *Z Hautkr* 1996;71:910–914.
8. Hohenleutner U, Bäuml W, Karrer S, Michel S, Landthaler M. Die Behandlung kindlicher Hämangiome mit dem blitzlampengepumpten gepulsten Farbstofflaser. *Hautarzt* 1996;47:183–189.
9. Michel S, Wlotzke U, Landthaler M. Laser- und Kryotherapie der Säuglingshämangiome im direkten Vergleich. *Hautarzt* 1998;49:192–196.
10. Adrian RM. Treatment of leg telangiectasias using a long-pulse frequency-doubled neodymium:YAG laser. *Dermatol Surg* 1998;24:19–23.
11. Adrian RM, Tanghetti EA. Long pulse 532-nm laser treatment of facial teleangiectasia. *Dermatol Surg* 1998;24:71–74.
12. Bethge S, Stadler R. Der langgepulste frequenzverdoppelte Neodymium:YAG Laser in der Behandlung von Besenreisern - erste klinische Erfahrungen. *Hautarzt* 1998;50:181–185.
13. Dierickx CC, Farinelli WA, Anderson RR. Clinical and histological responses of blood vessels to long (msec) 532 nm laser pulses. *Lasers Surg Med* 1996;S8:266.
14. Dierickx CC, Farinelli WA, Flotte T, Anderson RR. Effect of long-pulsed 532 nm Nd-YAG laser on portwine stains (PWS). *Lasers Surg Med* 1996;S8:188.
15. West TB, Alster TS. Comparison of the long-pulse dye (590–595nm) and the KTP (532 nm) lasers in the treatment of facial and leg teleangiectasias. *Dermatol Surg* 1998;24:221–226.
16. Anderson RR, Parrish RR. Selective photothermolysis: precise microsurgery by selective absorption of pulsed radiation. *Science* 1983;220:542–527.
17. Fiskerstrand EJ, Svaasand LA, Kopstad G, Ryggen K, Aase S. Photothermally induced vessel-wall necrosis after pulsed dye laser treatment: lack of response in port-wine stains with small sized or deeply located vessels. *J Invest Dermatol* 1996; 107:671–675.
18. van Gemert MJC, Welch AJ, Amin AP. Is there an optimal treatment for portwine stains? *Lasers Surg Med* 1986;6:76–83.
19. Dierickx CC, Casparian JM, Venugopalan V, Farinelli WA, Anderson RR. Thermal relaxation of port wine stain vessels probed in vivo: the need for 1-10-millisecond laser pulse treatment. *J Invest Dermatol* 1995;105:709–714.