

# Pulsed Dye Laser Treatment is Effective in the Treatment of Recalcitrant Viral Warts

ULRIKE SCHELLHAAS, MD,\* WOLFGANG GERBER,\* STEFAN HAMMES, MD,† AND HANS M OCKENFELS, MD\*

**BACKGROUND** Verrucae vulgaris can be removed in a variety of ways but a specific therapy of choice has not yet been developed. Doctors are faced with a challenge, especially in the treatment of recalcitrant warts. It has been suggested that the success of pulsed dye laser treatment lies in the fact that warts contain an increased number of dilated blood vessels.

**METHODS** Seventy-three patients (42 female, 31 male) with verrucae vulgaris on their hands or feet (1:1.5) were given a maximum of 12 treatments with a flashlamp-pumped pulsed dye laser every 2 weeks over a period of 24 weeks until complete clearance had been achieved. A laser energy density of 8 to 12 J/cm<sup>2</sup> with a spot size of 5 mm and a pulse duration of 450 μsec were used. The minimum follow-up period was 6 months.

**RESULTS** A total of 15.1% patients achieved complete clearance after 1 session and 47.9% after 2 to 5 sessions, resulting in a remission of 63.0% patients after a maximum of 5 treatment sessions. A remission of 23.3% patients was seen after 6 to 9 treatments and a total of 89.0% of patients showed remission after a maximum of 10 sessions. Only three patients (4.1%) failed and five patients (6.9%) stopped the treatment on account of pain/noncompliance. Only one patient, from a group of patients treated between January 2003 and April 2004, has relapsed.

**CONCLUSION** Pulsed dye laser treatment is effective and safe in the treatment of recalcitrant viral warts.

*The authors have indicated no significant interest with commercial supporters.*

Warts are benign epithelial proliferations induced by several types of the human papillomavirus (HPV). It is a common problem affecting approximately 10% of the population.<sup>1,2</sup> Warts often cause pain and may interfere with function. These complications, cosmetic embarrassment, and the risk of spreading to other areas of skin are indications for treatment,<sup>3</sup> which can be a challenge. Effective therapy means a considerable reduction of pain and an improvement in the quality of life. There are numerous treatments available, including destructive agents (keratolytics, cryotherapy, curettage and electrocautery, CO<sub>2</sub> laser, photodynamic therapy), immunosuppressive (podophyllin, bleomycin, retinoids) immune-modulating agents, or topical virucidal agents (formaldehyde, glutaral).<sup>3</sup> Failure to respond or the appearance of new lesions and the pain after surgical treatment combined with a long

period of functional insufficiency at work constitute a high economic factor,<sup>4</sup> which has, so far, been underestimated. Cure rates are described in literature for simple warts as being between 56 and 80% for common therapies, including salicylic acid, cryotherapy, 5-fluorouracil, and carbon dioxide laser therapy.<sup>5-12</sup> We have shown in a study that the cure rate of carbon dioxide laser reaches 77%, but recidivism is high at a rate of 22.6%.<sup>13</sup> Warts that fail to respond to conventional treatment are considered to be recalcitrant. These lesions are often frustrating for the patient and pose a therapeutic problem. Berth-Jones and Hutchinson<sup>14</sup> reported cure rates of 41 and 52% when treating a mixture of simple and recalcitrant warts with topical agents or cryotherapy. Several authors have recently reported that treatment with the flashlamp-pumped dye laser is a new, safe, and efficient therapy to treat simple and

\*Department of Dermatology and Allergy, Klinikum Stadt Hanau, Hanau; †Laserklinik Karlsruhe, Karlsruhe, Germany

recalcitrant warts.<sup>1,5,15-24</sup> Methods vary greatly in these publications, however, leading to response rate results which fluctuate between 0 and 95%. Reasons for this are that either the group of patients was too small ( $n=7$ ), that an evaluation was taken in retrospect, and that there was no prospective study or inclusion of patients with normal and not with recalcitrant warts.

In addition to the comparable analysis of available literature, the aim of our study, if successful, was to provide an exact definition of our therapeutic procedure to be able to offer a specific therapy recommendation when treating recalcitrant verrucae with the pulsed dye laser (PDL).

### Material and Methods

Seventy-three patients (42 female, 31 male) with verrucae vulgaris on their hands or feet (1:1.5) were enrolled in a prospective study over a period of 16 months from January 2003 until April 2004. The age of the patients was from 6 to 75 years (mean, 34.39 years), with 1 to 40 warts. The warts had been present for a mean of 3.63 years (range, 6 months to 25 years). The warts on the feet could all be found on the soles, whereas the warts on the hands were not only on the palms but also on the fingertips and, in nine cases, in the subungual regions.

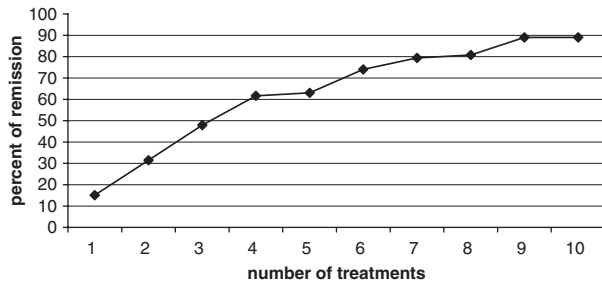
The criteria for defining warts as recalcitrant was that the area had been affected for more than 6 months and had been treated at least once without success. This treatment took the form of a series of up to eight sessions of conventional therapy with liquid nitrogen cryotherapy every 2 weeks or one surgical treatment using conventional surgical methods. All patients had been informed and had given their written consent. The sessions took place every 2 weeks. The study was concluded when complete remission had been achieved and follow-up was at 6 months. Complete response was defined as complete absence of verrucae with the presence of dermatoglyphics. We were not interested in partial remission because these warts start to grow back at

the end of treatment. Warts were individually counted and measured at the time of each treatment session. Before treatment, warts were pared with a scalpel to remove hyperkeratotic skin or debris just to the point of bleeding. Paring allows deeper penetration of the laser beam into the wart. Treatment took place without any form of anaesthetic. We used a flashlamp-pumped dye laser (PhotoGenica-V, Cynosure Inc., Westford, MA; 583 to 587 nm, 450  $\mu$ sec). Laser energy density was approximately 8 to 12 J/cm<sup>2</sup> with a spot size of 5 mm and a pulse duration of 450  $\mu$ sec. We used a dose of 8 J at the beginning of treatment to see how the patient reacted and increased this to 10 J at the second session and 12 J from the third session onward (if still necessary). Three to five shots were necessary at each site depending on the size and thickness of the warts before a livid discoloration, a known PDL side effect, became visible. This livid discoloration, which persists for up to 10 to 14 days, enables the doctor to decide whether the dose is correct. If there is no discoloration and the patient does not feel a "pinprick," then the dose of the individual pulse per site is not sufficient. Healthy skin surrounding the site was treated up to 1 to 2 mm.

All patients and the providers wore protective eyeglasses. The patient was allowed normal activity, and no bandage was necessary. Treatment, keratolytica, etc., were not performed at home.

### Results

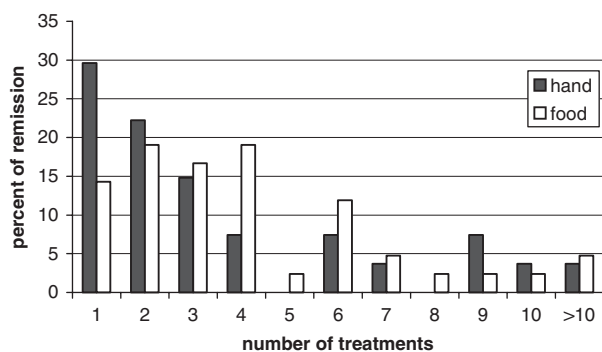
Sixty-eight of the 73 patients who were initially enrolled completed the treatment. Five patients withdrew because of side effects and/or pain from treatment, which was described as pinpricks. The other patients tolerated the treatment very well. They complained of pain, comparable to cryotherapy, and/or a burning sensation when the lasered site was touched up to 2 days after treatment. Unlike other usual PDL sites (face), purpura on the lasered sites on the hands and feet do not bother anyone. A total of 366 warts were treated. A total 15.1% patients were clear after 1 session and 47.9% after



**Figure 1.** Cumulative clearance.

2 to 5 sessions. This represented a clearance rate of 63.0% after a maximum of 5 sessions. A total 23.3% patients showed remission after 6 to 9 treatment sessions and 2.7% after 10 sessions. In summary, a total of 89.0% of patients showed remission after a maximum of 10 sessions. Only three patients (4.1%) failed the treatment with a flashlamp-pumped dye laser. These were patients who had had more than 10 treatment sessions and were defined as nonresponders. Therapy was discontinued in the nonresponder group after 12 sessions. We needed a mean of 3.7 treatment sessions for clearance. There was only one relapse over a period of 2 to 6 months, which was observed after treatment. The results are also shown in Figure 1 (cumulative clearance refers to number of patients). Results are shown in Figure 2 depending on the location of the warts. Warts on the hands (mean of 3.3 treatment sessions) cleared up quicker than warts on the feet (mean of 3.8 treatment sessions).

Statistically, the position and size of the warts (e.g., subungual) did not significantly correspond to a



**Figure 2.** Number of sessions needed depending on the location of the warts.

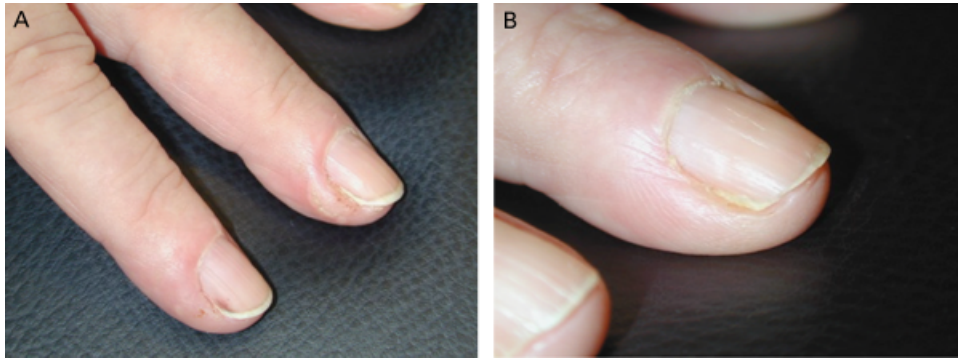
higher nonresponder rate. Illustrations of patients treated are shown in Figures 3 through 6.

## Discussion

Many different types of therapy have been used in the treatment of warts but treating verrucae is a therapeutic challenge. Warts have a high recidivism, and the pain after surgery combined with a long period of functional deficiency is a big problem. Treatment using local agents has a remission rate of approximately 56% to 80% but these results mostly apply to simple warts.<sup>5,7-12</sup>

Imiquimod has been found to be a topical immune response modifier agent that inhibits angiogenesis and is used to treat a broad range of angiogenesis-dependent dermatologic conditions, including actinic keratosis and basal cell carcinoma and external genital warts. Despite the good results in treating genital warts, only 30% of recalcitrant cutaneous warts responded to imiquimod.<sup>25</sup>

Recalcitrant wart treatment is more difficult and often frustrating. Berth-Jones and Hutchinson<sup>14</sup> attained a cure rate of only a maximum of 52% by treating recalcitrant warts using a combination of cryotherapy and topical paints. Recently, several researchers have discussed the effectiveness of PDL treatment for use in recalcitrant verrucae therapy. The heat and immunologic processes and the removal of the blood supply to the wart have been discussed with regard to the effectiveness of PDL in verrucae therapy.<sup>5,26</sup> The wavelength of the PDL is found in the yellow light spectrum (585 nm), which is absorbed from hemoglobin and oxyhemoglobin. Therefore, the laser is normally used in vascular malformation therapy.<sup>5,23</sup> Warts contain dilated, congested blood vessels in the dermal papillae extending along the rete ridges.<sup>27</sup> Oxyhemoglobin within the corpuscles in the dermal capillaries preferentially adsorbs this yellow light leading to selective microvascular destruction.<sup>5</sup> Heat is developed during the resorption of the light by the corpuscles. The result is a papillary purpura

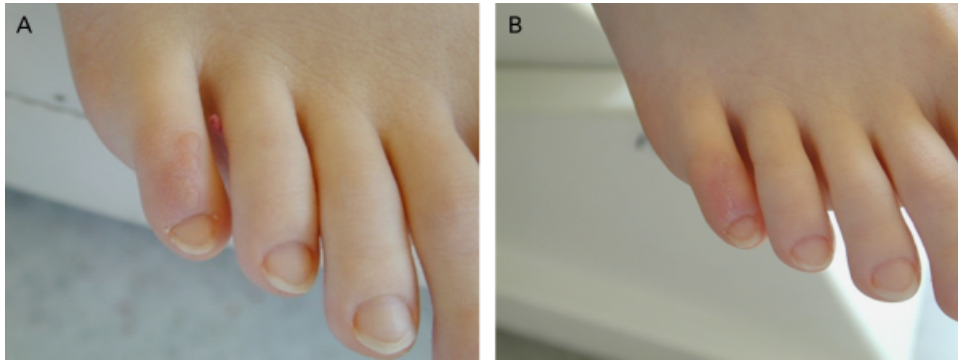


**Figure 3.** Seventy-six-year-old woman with periungual warts on her hands (A) and result after five treatment sessions (B). The warts had previously been resistant to treatment with virucidal agents, cryosurgery, and curettage.

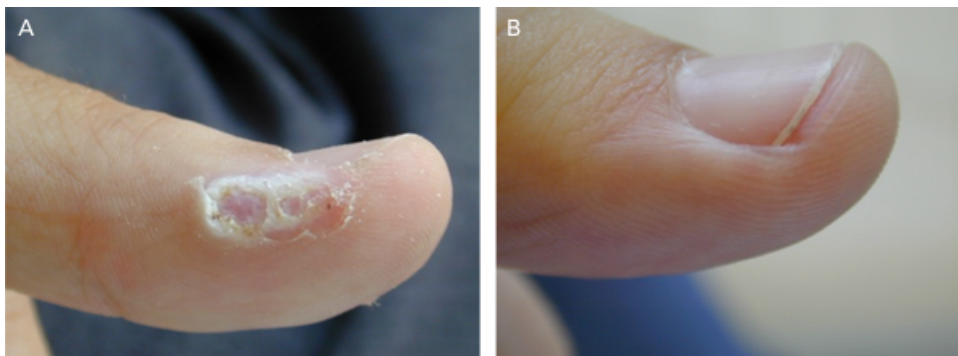
which will be resorbed by macrophages within 10 days. The effect on warts has been discussed controversially in literature.<sup>1,5,15-24,28</sup>

Only two studies describe a collective of more than 70 patients.<sup>22,28</sup> In both studies, recalcitrant and simple warts were treated with PDL. The cure rates

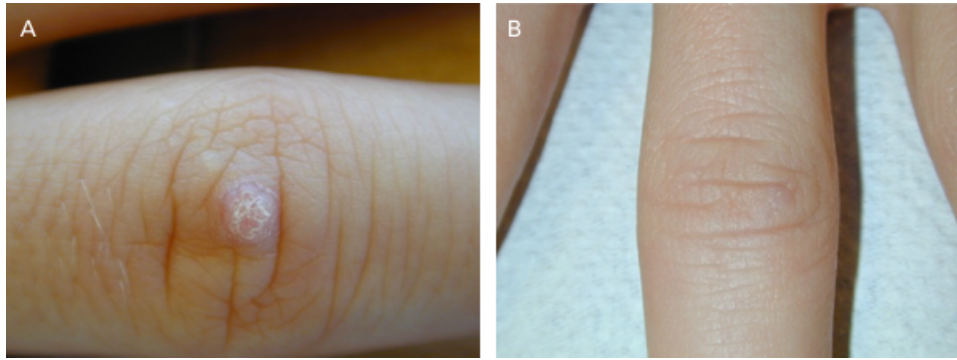
are described as being between 93% for warts on all sites after a mean of 2.5 treatment sessions by Kauvar and coworkers<sup>22</sup> and 62.7% after eight laser treatment sessions by Kopera.<sup>28</sup> The good results of Kauvar and colleagues can be explained by the fact that, even in initial treatment, patients were included who did not have chronic warts but were generally



**Figure 4.** (A) Thirteen-year-old girl with warts on her toe for 6 months that were resistant to repeated cryotherapy and topical virucidal agents. (B) Clearance after five sessions.



**Figure 5.** Nineteen-year-old man with a verruca vulgaris on his thumb (A), treated three times (B).



**Figure 6.** (A) Eighteen-year-old man who had had warts for 6 months. (B) Complete clearance after only one session.

patients with warts. The study by Robson and colleagues<sup>18</sup> is similar.

Although the study by Robson and colleagues is a random study with a control group of patients with warts treated by cryotherapy, there is no distinction made between initial treatment or chronic case treatment. In contrast, other studies have fewer patients. Table 1 shows an overview of recent literature. The collective is also mainly a variety of simple and recalcitrant warts. The treatment failed completely in one study, but the author describes a collective of just 7 patients.<sup>29</sup> Our study is a prospective study that includes 73 patients. All patients had recalcitrant warts. We did not have a collective of a variety of simple and recalcitrant warts.

We have not described partial remission. Full remission was the aim for the cure rate in our study. Our study shows a cure rate of 89.0% for recalci-

trant warts after a maximum of 10 sessions. The mean was 3.7 treatment sessions. In addition to the publications by Kauvar and coworkers<sup>22</sup> and Kopera,<sup>28</sup> the PDL is an effective method in the treatment of problem recalcitrant warts. On account of the purchasing and maintenance costs and lack of general availability, however, we would only recommend it for treating warts on the hands and feet which have resisted conventional therapies for months. Owing to the spontaneous remission of verrucae and the good results of fortnightly cryotherapy, this or other conventional therapies should remain the therapies of choice.<sup>27</sup> As already mentioned above, the new immune stimulators, mainly imiquimod, are not seen as alternatives to cryotherapy and our experience has shown that the response rate for verrucae palmares and plantares is far too low. PDL therapy, however, is far superior to other methods in treating recalcitrant warts, particularly therapies using surgically destructive CO<sub>2</sub> or

**TABLE 1 Pulsed Dye Laser in the Treatment of Verrucae Vulgaris 1993–2003**

Year	Author	Patients	Partial remission (%)	Total remission (%)	No remission (%)
1993	Tan et al. <sup>31</sup>	39	18	72	
1995	Kauvar et al. <sup>22</sup>	142		95 palmar, 84 plantar	
1996	Huilgol et al. <sup>29</sup>	7			100
1997	Jain and Storwick <sup>16</sup>	33		70	
1997	Jacobson et al. <sup>20</sup>	32		68	
1999	Ross et al. <sup>17</sup>	33	45	48	17
1999	Kenton-Smith et al. <sup>5</sup>	28		92	
2000	Robson et al. <sup>18</sup>	40	87	66	
2001	Wimmersdorf et al. <sup>1</sup>	24	42	6.5	
2003	Kopera <sup>28</sup>	126	21	63	9.5

classical surgery. PDL is a safe method with low side effects, ranging from erythema, edema of the skin, crust formation, hematoma, and a burning pain, which are mainly tolerated by patients. The risk of cicatrix formation and pigment alteration is low.<sup>26</sup> Adnexa of skin such as hair follicle and sweat glands are not destroyed.<sup>30</sup>

## Conclusion

We found that therapy using the PDL is a very effective and well-tolerated therapy for recalcitrant warts. It is also a very safe method with low side effects. Therefore, PDL therapy can be developed into a therapy of choice for recalcitrant warts.

## References

1. Wimmersdorf MB, Scherer K, Baumler W, et al. Treatment of therapy-resistant verruca vulgaris with long-pulsed tunable dye laser. *Hautarzt* 2001;52:701–4.
2. Rowson KE, Mahy BW. Human parpova (wart) virus. *Bacteriol Rev* 1967;31:110–31.
3. Leman JA, Benton EC. Verrucas, guidelines for management. *Am J Clin Dermatol* 2000;1:143–9.
4. Hengge U. Warzenbehandlung, evidenzbasiert. *J Deutsche Dermatol Gesellschaft* 2004;2:169–70.
5. Kenton-Smith J, Tan ST. Pulsed dye laser therapy for viral warts. *Br J Plast Surg* 1999;52:554–8.
6. Logan RA, Zachary CB. Outcome of carbone dioxide laser therapy for persistent cutaneous viral warts. *Br J Dermatol* 1989;121:99–105.
7. Rowson KE, Mahy BWJ. Human parpova (wart) virus. *Bacteriol Rev* 1967;31:110–31.
8. Zschocke I, Hartmann A, Schlobe A, et al. Efficacy and benefit of a 5-FU/salicylic acid preparation in the therapy of common and plantar warts-systematic literature review and meta-analysis. *J Deutsche Dermatol Gesellschaft* 2004;2:187–93.
9. Gibbs S, Harvey I, Sterling J, et al. Local treatments for cutaneous warts: systematic review. *BMJ* 2002;325:461.
10. Bunney MH, Nolan MW, Williams DA. An assessment of methods of treating viral warts by comparative treatment trials based on a standard design. *Br J Dermatol* 1976;94:667–79.
11. Burnett JW, Crutcher WA. In: Moschella S, Hurley H, editors. *Dermatology*. 2nd ed, Vol. 2. Philadelphia: Saunders; 1985. p. 694–6.
12. Bourke JF, Berth-Jones J, Hutchinson PE. Cryotherapy of common viral warts at intervals of 1, 2 and 3 weeks. *Br J Dermatol* 1995;132:433–6.
13. Ha AT, Ockenfels HM. Retrospektive analyse der rezidivhaufigkeit von verrucae vulgares nach CO<sub>2</sub>-laserablation. *J Deutsche Dermatol Gesellschaft* 2003;Band 1(Suppl I):215.
14. Berth-Jones J, Hutchinson PE. Modern treatment of warts: cure rates at 3 and 6 months. *Br J Dermatol* 1992;4:1035–40.
15. Borovoy MA, Borovoy M, Elson LM, et al. Flashlamp pulsed dye laser (585 nm). Treatment of resistant verrucae. *J Am Podiatr Med Assoc* 1996;86:547–50.
16. Jain A, Storwick GS. Effectiveness of the 585-nm-flashlamp-pulsed tunable dye laser (PTDL) for treatment of plantar verrucae. *Lasers Surg Med* 1997;21:500–5.
17. Ross BS, Levine VJ, Nehal K, et al. Pulsed dye laser treatment of warts: an update. *Dermatol Surg* 1999;25:377–80.
18. Robson KJ, Cunningham NM, Kruzan KL, et al. Pulsed-dye laser versus conventional therapy in the treatment of warts: a prospective randomized trial. *J Am Acad Dermatol* 2000;43(2 Pt 1):275–80.
19. Kauvar AN, Geronemus RG. Pulsed-dye laser versus conventional therapy in the treatment of warts. *J Am Acad Dermatol* 2001;45:151–2.
20. Jacobson E, McGraw R, McCagh S. Pulsed dye laser efficacy as initial therapy for warts and against recalcitrant verrucae. *Cutis* 1997;59:206–8.
21. Webster GF, Satur N, Goldmann MP, et al. Treatment of recalcitrant warts using the pulsed dye laser. *Cutis* 1995;56:230–2.
22. Kauvar AN, McDaniel DH, Geronemus RG. Pulsed dye laser treatment of warts. *Arch Fam Med* 1995;4:1035–40.
23. Kopera D. Verrucae vulgares. Treatment with 585-nm flashlamp pumped dye laser. *Hautarzt* 2002;53:604–7.
24. Vargas H, Hove CR, Dupree ML, et al. The treatment of facial verrucae with the pulsed dye laser. *Laryngoscope* 2002;112:1573–6.
25. Harwood CA, Perret CM, Brown VL, et al. Imiquimod cream 5% for recalcitrant cutaneous warts in immunosuppressed individuals. *Br J Dermatol* 2005;152:122–9.
26. Raulin CH, Greve G. *Laser und IPL-Technologie in der Dermatologie und Ästhetischen Medizin*. Stuttgart: Schattauer Verlag; 2001;Vol. 24, p. 149.
27. Lever WF, Schaumberg-Lever G. *Diseases caused by viruses. Histopathology of the skin*. Philadelphia: JB Lippincott Co; 1983. p. 371–6.
28. Kopera D. Verrucae vulgares: flashlamp-pumped pulsed dye laser treatment in 134 patients. *Int J Dermatol* 2003;42:905–8.
29. Huilgol SC, Barolw RJ, Markey AC. Failure of pulsed dye laser therapy for resistant verrucae. *Clin Exp Dermatol* 1996;21:93–5.
30. Landthaler M, Hohenleutner U. *Lasertherapie in der dermatologie*. Springer Verlag; 1999. p. 16.
31. Tan OT, Hurwitz RM, Stafford TJ. Pulsed dye laser treatment of recalcitrant verrucae preliminary report. *Lasers Surg Med* 1993;13:127–37.

---

Address correspondence and reprint requests to:  
Hans M. Ockenfels, MD, Chairman, Department of  
Dermatology and Allergy, Leimenstr. 20, Klinikum Hanau,  
Germany, or e-mail: hautklinikum-hanau@ndh.net