

# The Combined Continuous-Wave/Pulsed Carbon Dioxide Laser for Treatment of Pyogenic Granuloma



Christian Raulin, MD; Baerbel Greve, MD; Stefan Hammes, MD

**Background:** Pyogenic granuloma is a frequently diagnosed, benign vascular lesion.

**Objectives:** To present the use of the combined continuous-wave/pulsed carbon dioxide (CO<sub>2</sub>) laser as an innovative therapeutic method, to compare it with established methods, and to assess its results.

**Design:** Prospective observational study between March 1998 and July 2000, comprising 1 treatment session with 6-week and 6-month follow-up examinations and evaluations.

**Setting:** Private or institutional practices as well as ambulatory or hospitalized care.

**Patients:** One hundred patients with pyogenic granuloma selected from a population-based sample.

**Interventions:** Treatment with CO<sub>2</sub> laser. The laser was first used in continuous mode (power, 15 W) and then in pulsed mode (pulse length, 0.6-0.9 milliseconds; energy fluence, 500 mJ/pulse).

**Main Outcome Measure:** Complete resolution of treated granuloma pyogenicum.

**Results:** Pyogenic granuloma was removed completely in 1 treatment session in 98 patients without recurrence. In 88 cases there were no visible scars; in 10 cases slight textural changes of the skin were observed. Hypertrophic scars or keloids did not occur. Sixty-three patients were very satisfied with the result of the treatment, 37 were satisfied (ie, 100% patient satisfaction), and none indicated that they were not satisfied. No permanent hypopigmentation, hyperpigmentation, or erythema was observed.

**Conclusions:** The combined continuous-wave/pulsed CO<sub>2</sub> laser is our treatment of choice for pyogenic granuloma because this kind of laser is widely available, produces excellent results with few adverse effects, is easy to use, yields low recurrence rates, and is well tolerated by most patients.

*Arch Dermatol.* 2002;138:33-37

**P**YOGENIC GRANULOMA is a frequently diagnosed, benign vascular lesion. Possible treatment methods are excision, curettage, cryotherapy, chemical and electric cauterization, and the use of lasers.<sup>1-5</sup> The argon laser has long been used to treat pyogenic granuloma, but its use may be associated with an increased risk of scarring.<sup>6</sup> In one case, a large gingival pyogenic granuloma was removed with a continuous-wave (CW) Nd:YAG laser.<sup>5</sup> There are several reports about the use of the pulsed dye laser,<sup>3,7,8</sup> although it has only been successfully used in removing very small granulomas; several treatment sessions were necessary in most cases.<sup>8,9</sup> In the past few years, the CW carbon dioxide (CO<sub>2</sub>) laser has proved to be an effective treatment option.<sup>10</sup> Its use permits rapid, minimally invasive surgical treatment, but the nonspecific coagulation may lead to scars.

In 1997, we first reported the successful combined use of CW and pulsed CO<sub>2</sub> lasers in a retrospective pilot study<sup>10</sup> that involved 13 patients. The CW laser was used to coagulate the lesion, and the pulsed CO<sub>2</sub> laser to treat the base carefully; the correct use of the latter permits the skin to heal with minimal scarring. These positive results and the simplicity of the method encouraged us to evaluate it further and carry out the present prospective study with 100 patients.

## RESULTS

The pyogenic granuloma was removed completely in 1 session without recurrence in 98 patients; recurrence was observed in only 2 patients. There were no visible scars in 88 cases, and slight textural changes were observed in 10. Small atrophic scars were documented in

From the Laserklinik  
Karlsruhe, Karlsruhe,  
Germany.

## PATIENTS AND METHODS

In a prospective study conducted between March 1998 and July 2000, we used the CO<sub>2</sub> laser (10 600 nm) (UltraPulse 5000 C; Coherent Inc, Palo Alto, Calif) to treat 100 patients (57 female and 43 male) with pyogenic granuloma (**Table 1**). Their age ranged between 6 months and 84 years (mean, 26.8 years; median, 24.9 years). The laser was first used in continuous mode (power, 15 W; focused handpiece with variable spot size of 1.5-3.0 mm) and then in pulsed mode (pulse length, 0.6-0.9 milliseconds; fluence, 500 mJ/pulse), with the same handpiece. Prior to laser therapy, intracutaneous local anesthetic (1% lidocaine [1% Xylocaine; AstraZeneca GmbH, Wedel, Germany]) was administered in 98 cases; a brief general anesthesia was selected for the treatment of 2 children. Postoperative erosions and the crusting that occurred after some days were treated with iodine ointment.

In 58 cases, the granulomas were localized on the face (cheek, 18; lips, 12; tongue, 1; and other, 27); in 17 cases, on the fingers; and in 25 cases, elsewhere on the integument. The diameter of the lesions measured less than 0.3 cm in 23 cases, 0.3 to 0.6 cm in 64 cases, and greater than 0.6 cm in 13 cases. In 5 cases the granulomas had occurred as an adverse effect of a prior laser treatment of port-wine stains (4 after treatment with pulsed dye laser, 1 after argon laser treatment). In 4 cases the granulomas were recurrences after excisions carried out in other surgeries. A summary of the demographic data is given in Table 1.

The study design comprised a 1-treatment session with 6-week and 6-month follow-up examinations and evaluations conducted by 3 independent physicians who were not involved in the study as well as by the patients (or their parents). In this context, the following data and scales were used by the patients: satisfaction with the result (0, very satisfied; 1, satisfied; 2, not satisfied), healing process (0, very satisfied; 1, satisfied; 2, not satisfied). The evaluating physicians used the following data and scales: duration of healing (data given in weeks), recurrence (Boolean value), hypopigmentation or hyperpigmentation (0, none; 1, transient hypopigmentation or hyperpigmentation; 2, permanent hypopigmentation or hyperpigmentation), scars (0, no visible scars; 1, slight textural changes of the skin; 2, atrophic scars; 3, hypertrophic scars; 4, keloids), erythema (0, none; 1, transient; 2, permanent), duration of erythema (weeks). Photographic documentation was done at the beginning and at the end of the study (EOS100 [Canon USA, Inc, Lake Success, NY] with Agfachrome CTx 100 film [Agfa Corp, Ridgefield Park, NJ]).

2 cases, and hypertrophic scars or keloids did not occur at all.

Sixty-three patients found the treatment results very satisfactory; 37, satisfactory; and none said that it was unsatisfactory. In terms of patient response to the healing process, the reactions were quite similar: 41 found it

**Table 1. Demographic Data**

Characteristic	Value*
Sex	
Female	57
Male	43
Age, y	
Mean	26.8
Median	24.9
Range	0.5-84
Fitzpatrick skin types	
I	34
II	52
III	14
Location of lesion	
Face or neck	58
Cheek	18
Lips	12
Tongue	1
Other	27
Fingers	17
Other integument	25
Diameter of lesion, cm	
<0.3	23
0.3-0.6	64
>0.6	13
Prior treatment	
Cryotherapy	12
Dye laser	8
Excision	4
Development due to dye or argon laser therapy	5
Treatment	
General anesthesia	2 (ages 3 and 7 y)
Local anesthesia (1% lidocaine)	98

\*Values are number of patients (N = 100) unless otherwise indicated.

very satisfactory; 59%, satisfactory; and none, unsatisfactory. In our evaluation, the answers "satisfied" and "very satisfied" were taken as an indication that the operation was successful and appreciated by the patient. Therefore, we had 100% patient satisfaction. The difference between "satisfied" and "very satisfied" was only gradual and perhaps based on different patient expectations.

The healing process (defined as re-formation of the epidermal integrity after disappearance of the crusts) lasted up to 1 week in 52 patients, up to 2 weeks in 41, and up to 3 weeks in 7. No hypopigmentation or hyperpigmentation was observed in 88 cases; transient hypopigmentation or hyperpigmentation occurred in 12 (lasting up to 6 months). No permanent hypopigmentation or hyperpigmentation occurred. In 62 cases, the erythema had disappeared after 6 weeks. For the remaining 38, the erythema had resolved before the second follow-up examination (total duration under 6 months). On average, the erythema persisted for 3.5 weeks. Permanent erythema was not observed. A summary of the results is given in **Table 2**. **Figures 1, 2, and 3**, show pretreatment and posttreatment status for 3 typical patients.

### COMMENT

So far, surgical excision or electrocoagulation has been considered the standard treatment of pyogenic granuloma.<sup>2</sup> However, because of the remaining scars, exci-

sion is a suboptimal form of therapy, especially since the lesions often occur in exposed places such as the face or fingers. Bleeding can also complicate the operation process, especially in huge granulomas or if the excision is close to the lesion.

The use of the pulsed dye laser can yield excellent cosmetic results, although several treatment sessions are necessary.<sup>1,9,11</sup> Owing to its limited penetration depth, this kind of laser can only be used to treat small granulomas. Tay et al<sup>9</sup> showed that a successful treatment is possible only with granulomas of a diameter smaller than 5 mm. Using the pulsed dye laser, we could remove only lesions with a maximum diameter of 2.5 mm success-

fully. There are reports about the induction of pyogenic granuloma due to the use of the dye laser, potassium-titanyl-phosphate-Nd:YAG laser, and argon laser, as well as by cryosurgery.<sup>12-18</sup> The etiological data of our study confirms this observation for the dye and argon lasers. Any laser therapy should only be done if it is certain that the lesion is benign. If there is any doubt, conventional surgical methods or laser treatment should be used only with histological confirmation.

The CO<sub>2</sub> laser emits radiation with a wavelength of 10600 nm, which is absorbed by the water in biological structures. The laser energy destroys the integrity of the cellular structure by quickly heating and vaporizing the intracellular liquid. Target structures such as pigmentation or vascularization are of no importance for the CO<sub>2</sub> laser,<sup>19,20</sup> which is unlike other kinds of lasers such as the Q-switched ruby laser or the pulsed dye laser. There is a certain risk of scars due to the unspecific coagulation in the continuous mode.

In case reports<sup>21</sup> and in our pilot study,<sup>10</sup> the use of the CW CO<sub>2</sub> laser has proved to be an effective method to treat pyogenic granuloma. Kirschner and Low<sup>22</sup> described the combined use of shaving and photocoagulation with pulsed dye laser. Here, the advantage of the histological confirmation must be balanced against the increased risk of bleeding, which, in our experience, may not be well controlled by dye laser irradiation, especially in deep or large granulomas.

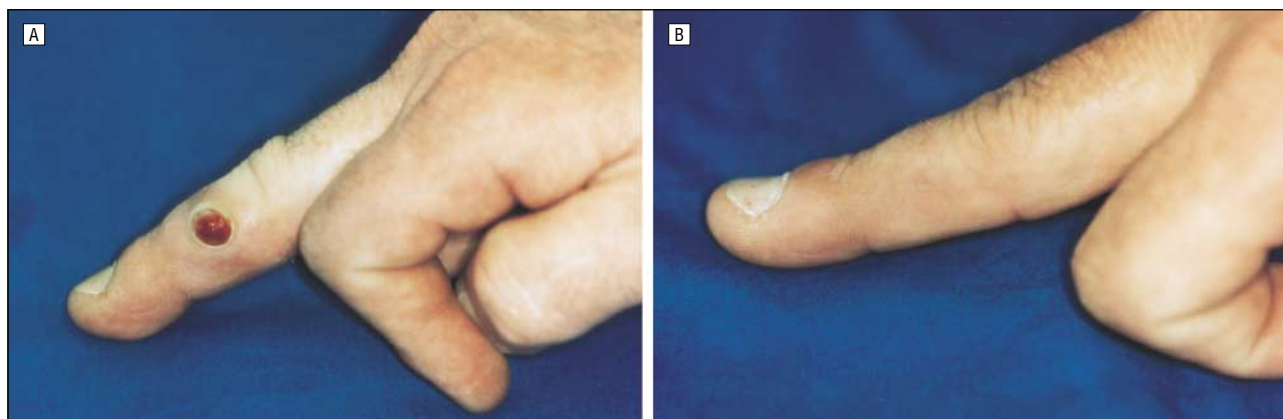
For some years now, pulsed (<1 millisecond) CO<sub>2</sub> lasers have been used in addition to the CW CO<sub>2</sub> laser in dermatology and plastic surgery. The pulse length of these lasers is 600 to 900 μs and is shorter than the thermal relaxation time of the epidermal cells (695 to 950 microseconds); thus, thermal damage in the surrounding tissue can be neglected. When used correctly, the pulsed CO<sub>2</sub> laser makes it possible to remove very thin skin layers without leaving scars.<sup>4,19,20,23</sup> The risk of scarring cannot be ruled out entirely because the basement membrane can be destroyed when several treatment passes are used.<sup>24</sup>

In the present study, pyogenic granulomas were removed successfully with low rates of concomitant reactions or adverse effects; this was due to the combined use of continuous and pulsed mode of the CO<sub>2</sub> laser. The continuous mode leads to rapid and minimally invasive coagulation of the vascular lesion. This is, in principle, also

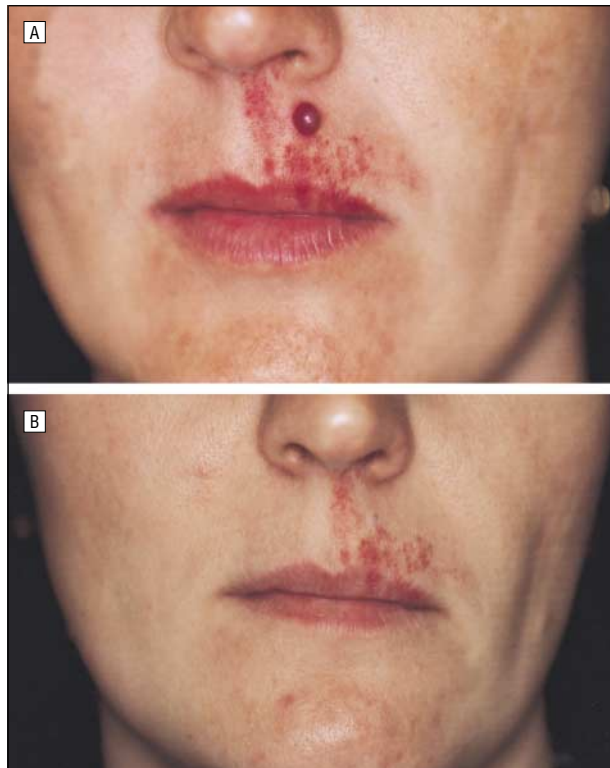**Table 2. Results of Treatment With the Combined Continuous-Wave/Pulsed Carbon Dioxide Laser\***

Duration of healing, wk	
1	52
2	41
3	7
Erythema	
None (after 6 wk)	62
Transient (up to 6 mo)	38
Permanent	0
Hypopigmentation or hyperpigmentation	
None (after 6 wk)	88
Transient (up to 6 mo)	12
Permanent	0
Scars	
No visible scars	88
Slight textural changes of the skin	10
Atrophic scars	2
Hypertrophic scars	0
Keloids	0
Recurrence	
No	98
Yes	2
Subjective satisfaction with the result	
Very satisfied	63
Satisfied	37
Not satisfied	0
Subjective satisfaction with the healing process	
Very satisfied	41
Satisfied	59
Not satisfied	0

\*All values are number of patients (N = 100).



**Figure 1.** A, Patient with pyogenic granuloma on the finger. B, Status 6 weeks after a single therapy session with the continuous-wave/pulsed carbon dioxide laser. The lesion has healed completely without scars.

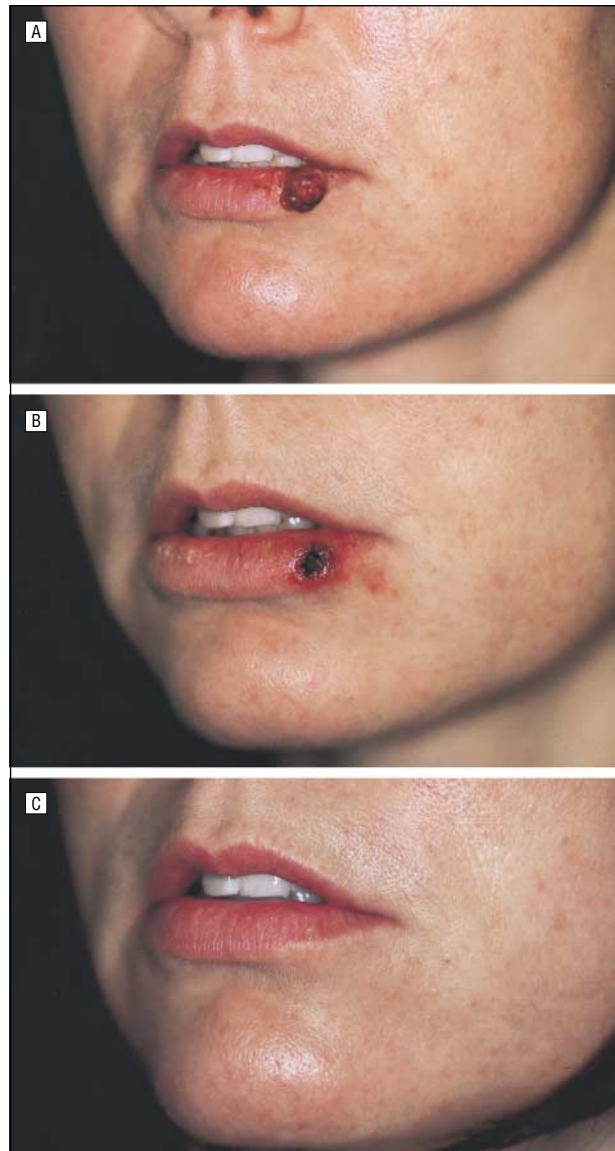


**Figure 2.** A, Patient with pyogenic granuloma on the upper lip. B, Status 5 weeks after a single therapy session with the continuous-wave/pulsed carbon dioxide laser. The lesion has healed completely without scars.

possible with other coagulating lasers (eg, argon and CW Nd:YAG), but when it comes to the delicate task of removing the basis of the lesion, vaporization in pulsed mode has proved to be advantageous. Extremely thin skin layers can be removed, thus allowing differences in skin levels to be gently evened out. This can only be achieved with pulsed CO<sub>2</sub> lasers.

In contrast to the pulsed dye laser, only 1 treatment session with the CO<sub>2</sub> laser was necessary in 98% of the cases. It is indeed a problem to find the correct point to switch from continuous to pulsed mode. We used the continuous mode until the lesion was flattened down to its ground and there were only capillary bleedings left. Then we switched to pulsed mode. It is critical to go deep enough to remove the granuloma entirely; the 2 recurrences that occurred in our study were probably due to an incomplete or overcautious removal, and they disappeared permanently after another treatment session.

The CO<sub>2</sub> laser has advantages over common operative methods: treatment and convalescence take considerably less time. An experienced physician needs a maximum of 5 minutes for the operation, even for big granulomas. There is no wound to close and no suture material to trigger allergic or foreign body reactions. With the CO<sub>2</sub> laser, it is no problem to treat the sites of predilection, which are usually difficult to access and are located on exposed parts of the body such as the eyelids, fingers, or toe phalanges. The method can accommodate large lesions, and it is equally suitable for patients who tend to bleed heavily. We see the use of the combined CW/pulsed CO<sub>2</sub> laser as the treatment of choice



**Figure 3.** A, Patient with pyogenic granuloma on the lower lip. B, Status immediately after operation. C, Status 7 weeks after a single therapy session with the continuous-wave/pulsed carbon dioxide laser. The lesion has healed completely with only slight textural changes.

for pyogenic granuloma because this kind of laser is widely available, produces excellent results with few adverse effects, is easy to use, yields low recurrence rates, and is well tolerated by most patients.

*Accepted for publication May 2, 2001.*

*We dedicate this article to Detlef Petzoldt, professor of dermatology and venereology, of the department of dermatology of the University of Heidelberg, Heidelberg, Germany, on the occasion of his 65th birthday. He has always been an extraordinary teacher for us and an excellent physician for his patients, and he has always focused on scientific innovation. We would like to thank Alexandra Sitzmann, MA, and Laura Russel, MA, for help with the translation of the text.*

*Corresponding author and reprints: Christian Raulin, MD, Laserklinik Karlsruhe, Kaiserstr 104, D-76133 Karlsruhe, Germany (e-mail: info@laserklinik.de).*

## REFERENCES

1. Goldberg DJ, Sciales CW. Pyogenic granuloma in children: treatment with the flashlamp-pumped pulsed dye laser. *J Dermatol Surg Oncol*. 1991;17:960-962.
2. Fitzpatrick TB, Eisen AZ, Wolff K, Freedberg IN, Austen KF, eds. *Dermatology in General Medicine*. New York, NY: McGraw-Hill Co; 1987:661.
3. Glass AT, Milgraum S. Flashlamp-pumped pulsed dye laser treatment for pyogenic granuloma. *Cutis*. 1992;49:351-353.
4. Goldman MP, Fitzpatrick RE. *Cutaneous Laser Surgery*. St Louis, Mo: Mosby-Year Book Inc; 1994:64.
5. Powell JL, Bailey CL, Coopland AT, Otis CN, Frank JL, Meyer I. Nd:YAG laser excision of giant gingival pyogenic granuloma of pregnancy. *Lasers Surg Med*. 1994;14:178-183.
6. Apfelberg DB, Maser MR, Lash H, Rivers JL. Progress report on extended clinical use of the argon laser for cutaneous lesions. *Lasers Surg Med*. 1980;1:71-83.
7. Gonzalez E, Gange RW, Momtaz KT. Treatment of telangiectases and other benign vascular lesions with the 577 pulsed dye laser. *J Am Acad Dermatol*. 1992;27:220-226.
8. Meffert JJ, Cagna DR, Meffert RM. Treatment of oral granulation tissue with the flashlamp pulsed dye laser. *Dermatol Surg*. 1998;24:845-848.
9. Tay YK, Weston WL, Morelli JG. Treatment of pyogenic granuloma in children with the flashlamp-pumped pulsed dye laser. *Pediatrics*. 1997;99:368-370.
10. Raulin C, Petzoldt D, Werner S. Granuloma pyogenicum: Entfernung mit dem CO<sub>2</sub>-Laser. *Hautarzt*. 1997;48:402-405.
11. Gonzalez S, Vibhagool C, Falo LD Jr, Momtaz KT, Grevelink J, Gonzalez E. Treatment of pyogenic granulomas with the 585-nm pulsed dye laser. *J Am Acad Dermatol*. 1996;35:428-431.
12. Abd-el-Raheen TA, Hohenleutner U, Landthaler M. Granuloma pyogenicum as a complication of flashlamp-pumped pulsed dye laser. *Dermatology*. 1994;189:283-285.
13. Wlotzke U, Hohenleutner U, Abd-El-Raheen TA, Baumler W, Landthaler M. Side-effects and complications of flashlamp-pumped pulsed dye laser therapy of port-wine stains: a prospective study. *Br J Dermatol*. 1996;134:475-480.
14. De Rooij MJ, Neumann HA. Granuloma telangiectaticum after argon laser therapy of a spider nevus. *Dermatol Surg*. 1995;21:356-357.
15. Beers BB, Rustad OJ, Vance JC. Pyogenic granuloma following laser treatment of a port-wine stain. *Cutis*. 1988;41:266-268.
16. Dejonckere PH, Franceschi D, Scholtes JL. Extensive granuloma pyogenicum as a complication of endolaryngeal argon laser surgery. *Lasers Surg Med*. 1985;5:41-45.
17. Cecchi R, Giomi A. Pyogenic granuloma as a complication of cryosurgery for venous lake. *Br J Dermatol*. 1999;140:373-374.
18. Raulin C, Greve B, eds. *Laser und IPL-Technologie in der Dermatologie und Ästhetischen Medizin*. Stuttgart, Germany: Schattauer; 2001.
19. Fitzpatrick RE, Goldman MP, Satur NM, Tope WD. Pulsed carbon dioxide laser resurfacing of photoaged facial skin. *Arch Dermatol*. 1996;132:395-402.
20. Lowe NJ, Lask G, Griffin ME, Maxwell A, Lowe P, Quilada F. Skin resurfacing with the ultrapulse carbon dioxide laser. *Dermatol Surg*. 1995;21:1025-1029.
21. Modica LA. Pyogenic granuloma of the tongue treated by carbon dioxide laser. *J Am Geriatr Soc*. 1988;36:1036-1038.
22. Kirschner RE, Low DW. Treatment of pyogenic granuloma by shave excision and laser photocoagulation. *Plast Reconstr Surg*. 1999;104:1346-1349.
23. Reid R. Physical and surgical principles governing carbon dioxide laser surgery on the skin. *Dermatol Clin*. 1991;9:297-316.
24. Raulin C, Kimmig W, Werner S. Lasertherapie in der Dermatologie und Ästhetischen Medizin: Nebenwirkungen, Komplikationen und Behandlungsfehler. *Hautarzt*. 2000;51:463-473.

### Announcement

#### Free Patient Record Forms Available

Patient record forms are available free of charge to ARCHIVES readers by calling or writing FORMEDIC, 12D Worlds Fair Dr, Somerset, NJ 08873-9863, telephone (908) 469-7031.