

Treatment of Sebaceous Gland Hyperplasia With the Pulsed Dye Laser

Matthias P. Schönemark, MD, Christian Schmidt, MD, and
Christian Raulin, MD

*Center for Dermatologic Laser Therapy, D-76133 Karlsruhe, Germany
and*

Department of Otolaryngology/Head and Neck Surgery, Hanover Medical School, D-30623 Hannover, Germany

Background and Objective: Sebaceous gland hyperplasia may be treated by cryotherapy, cauterization, topical chemicals, or excision. The major disadvantage of these therapeutic strategies is a considerable risk of postoperative scarring or dyspigmentation. The pulsed dye laser may be an effective and safe alternative treatment option. *Study Design and Methods:* Our report presents two patients with sebaceous gland hyperplasia who were treated with the pulsed dye-laser (585 nm, 6.5-8 J/cm², 800-450/microsec).

Results: After 2-3 treatment sessions, the lesions were completely gone. To date, no side effects have been observed.

Conclusions: Based upon our experiences, we recommend the pulsed dye laser as a safe, fast, and minimal straining treatment alternative for hyperplasia of sebaceous glands.

Key words: sebaceous gland hyperplasia; laser therapy; pulsed dye laser

INTRODUCTION

The established concepts for the treatment of sebaceous gland hyperplasia include cryotherapy, cauterization, excision of the lesion, and the topical application of drugs [1 – 3]. All of these strategies carry a considerable risk of disfigurative postoperative scarring or dyspigmentation. In addition, recurrence is a common phenomenon. Laser therapy of sebaceous gland hyperplasia has not been reported to date. We treated more than 40 patients with sebaceous gland hyperplasia with the pulsed dye laser. This treatment bypasses long operation hours, shortens the follow-up period, and when applied properly, does not lead to scar formation. The following two cases well demonstrate the effectiveness of the laser treatment.

MATERIALS AND METHODS Patients

Patient 1 was a 62-year-old woman who suffered from multiple hyperplastic lesions of the sebaceous glands, which were most prominent on the forehead (Fig. 1a). She was treated during three sessions with the pulsed dye laser (585 nm wavelength, 300 - 450 microsec pulse duration; Photo Genica V, Cynosure, Boston, MA). We used the 5 mm laser probe with an energy dose of 7 J/cm² in the first session and 8 J/cm² in the two consecutive sessions.

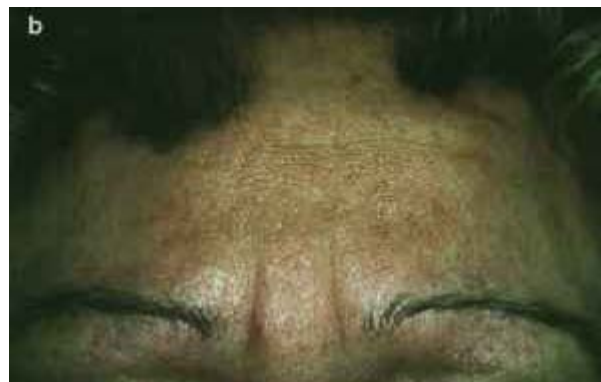
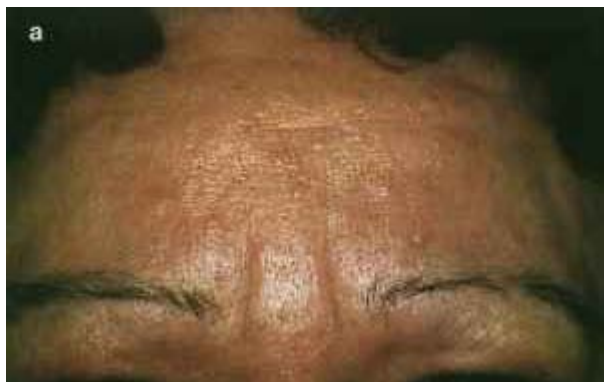
fig1: Sixty-two-year-old female patient with multiple sebaceous hyperplasia of the forehead: (a) before treatment, (b) after treatment sessions with the pulsed dye laser

Patient 2, a 58-year-old man, suffered from a single sebaceous gland hyperplasia of the forehead (Fig. 2a). Laser treatment was applied during two consecutive sessions (5 mm laser probe, 6.5 J/cm² and 6.8 J/cm² energy dose, respectively).




fig2: Fifty-year-old male patient with a single sebaceous gland hyperplasia of the forehead: (a) before treatment, (b) after two treatment sessions

RESULTS

The lesions of the female patient responded immediately to the first treatment and were completely gone after the third session (Fig. 1b). Nine months after treatment, no scarring or recurrence showed up. The sebaceous gland hyperplasia of the male patient disappeared completely after three consecutive treatments, and there is no recurrence or scarring after 13 months (Fig. 2b).

DISCUSSION

Hyperplasia of the sebaceous glands presents clinically as singular or multiple papulous lesions with a central umbo, which represents a dilated excretion duct. They appear predominantly on the forehead, nose, cheeks. The approximate diameter of the lesion is 2 – 3 mm [4], although in a few isolated cases, nodules up to 5 cm diameter have been reported [5 – 7]. Histologically, hyperplastic, sebaceous gland lobules can be seen that group around a central, massively dilated excretion duct [8]. Most of the cases are of

unknown origin, but some reports describe systemic corticoid therapy [9,10] or hemodialysis [11] as the main cause for the lesions. In a recent study of 420 normal Australian newborns, sebaceous gland hyperplasia was found in **48%** of the study group [12]. In Indian newborns, the prevalence of sebaceous hyperplasia was found to be **81.8%** [13]. In general, the lesions disappeared spontaneously within the first months of life. Multiple hyperplastic lesions of sebaceous glands also were found in Muir-Torre syndrome [14,15], in the X-chromosomal hypohidrotic ectodermal dysplasia syndrome (X-HED) [16], and in pachydermoperiostosis [4,17], where they define the disease. In Muir-Torre syndrome, the sebaceous gland alterations, together with the other mandatory dermatoses, indicate the high risk for gastrointestinal malignomas [14,15].

The classical therapeutic concept for the treatment of sebaceous gland hyperplasia includes cryotherapy, cauterisation, topical drugs, or surgical excision [1 – 3]. These measures bear a considerable risk of posttherapeutic scarring or dyspigmentation, intra- and postoperative bleeding, and recurrence of the lesions [18]. In contrast, treatment with the pulsed dye laser never leads to hypertrophic scars, and the risk for atrophic scar formation is **<0.1%** [19]. This is based on the focused destruction of dermal vessels by selective photothermolysis, which puts minimal stress on the surrounding tissue [20]. The exact mechanism of the pulsed dye laser in the treatment of sebaceous gland hyperplasia is not fully understood. We hypothesize the selective destruction of sebaceous gland supplying vessels, which in turn leads to a degeneration of the lesion [21].

In all our cases, the sebaceous gland hyperplasia could be removed with the pulsed dye laser in an outpatient setting. The treatment sessions were no longer than 10 min. One to three sessions in a 4-week interval were carried out. The moderate discomfort was easily endured by our patients. One day after treatment, a livid discoloration of the treatment area occurs, which resembles an intracutaneous hematoma. In general, we applied energy doses of 6-8 J/cm². Higher doses led to delicate crusts, which should not be removed. All lesions healed without scarring. The hyperplastic sebaceous glands disappeared completely. We did not observe any therapy failure or any postoperative scarring in any of our patients.

An alternative to the pulsed dye laser may be the pulsed carbon dioxide laser, or the pulsed Erbium-YAG laser. The optical energy of these laser types is strongly absorbed by the extracellular fluid, which causes a gentle "shaving" of thin tissue layers. In summary, the treatment of sebaceous gland hyperplasia with the pulsed dye laser is an easy-to-use, painless, and method, which carries minimal risk of scarring or other side effects. We see the pulsed dye laser as an innovative and rewarding treatment alternative for the therapy of sebaceous gland hyperplasia. Further studies will elicit the mode of action of the dye laser in this particular disease.

REFERENCES

1. Rosian R, Goslen JB, Brodell RT. The treatment of benign sebaceous hyperplasia with the topical application of bichloroacetic acid. *J Dermatol Surg Oncol* 1991;17: 876 – 879.
2. Grekin RC, Ellis CN. Isoretinoin for the treatment of sebaceous hyperplasia. *Cutis* 1984;34:90 – 92.
3. Wheeland RG, Wiley MD. Q-tip cryosurgery for the treatment of senile sebaceous hyperplasia. *J Dermatol Surg Oncol* 1987;13:729 – 730.
4. Jansen T, Brandl G, Bandmann M, Meurer M. Pachyder-moperiostose. *Hautarzt* 1995;46:429 – 435.
5. Kato N, Yasuoka A. "Giant" senile sebaceous hyperpla-sia. *J Derm* 1992;19:238 – 241.
6. Czarnecki DB, Dorevitch AP. Giant senile sebaceous hy-perplasia. *Arch Dermatol* 1986;122:1101.
7. Uchiyama N, Yamaji K, Shindo Y. Giant solitary sebaceous gland hyperplasia on the frontal region. *Dermato-logica* 1990;181:60 – 61.
8. Luderschmidt C, Plewig G. Circumscribed sebaceous gland hyperplasia: Autoradiographic and histoplanimet-ric studies. *J Invest Dermatol* 1978;70:207 – 209.
9. Chanoki M, Izutani K, Maeda T. Senile sebaceous hyper-plasia induced by corticosteroid therapy. *Hifuka No Rin-sho* 1985;39:897 – 902.
10. Bencini PL, Montagnino G, Sala F, De Vecchi A, Crosti C, Tarantino A. Cutaneous lesions in 67 cyclosporin-treated renal transplant recipients. *Dermatologica* 1986;172:24 – 30.
11. Terui T, Takahashi M. Sebaceous hyperplasia observed in hemodialysed patient. *Hifuka No Rinsho* 1986;28:193 – 196.
12. Rivers JK, Frederiksen PC, Dibdin C. A prevalence survey of dermatoses in the Australian neonate. *J Am Acad Dermatol* 1990;23:77 – 81.
13. Nanda A, Kaur S, Bhakoo ON, Dhall K. Survey of cutaneous lesions in Indian newborn. *Pediatr Dermatol* 1989; 6:39 – 42.
14. Schwartz RA, Torre DP. The Muir- Torre-syndrome: A 25year retrospect. *J Am Acad Dermatol* 1995;33:90 – 104.
15. Lynch HT, Fusaro RM, Roberts L, Vorhees GJ, Lynch JF. Muir-Torre syndrome in several members of a family with a variant of the Cancer Family Syndrome. *Br J Der-matol* 1985;113:295 – 301.
16. Orge C, Bonsmann G, Hamm H. Multiple Talgdriisen-hyperplasien bei X-chromosomaler hypohidrotischer ek-todermaler Dysplasie. *Hautarzt* 1991;42:645 – 647.
17. Matsui Y, Nishii Y, Maeda M, Okada N, Yoshikawa K. Pachydermoperiostosis-report of a case and review of 121 Japanese cases. *Nippon Hifuka Gakkai Zasshi* 1991;101: 461 – 467.
18. Schonermark MP, Raulin C. Treatment of Xanthelasma Palpebrarum with the pulsed dye laser. *Lasers Surg Med* 1996 (in press).
19. Levine VJ, Geronemus RG. Adverse effects associated with the 577- and 585 nanometer pulsed dye laser in the treatment of cutaneous vascular lesions: A study of 500 patients. *J Am Acad Dermatol* 1995;32:613 – 617.
20. Raulin C, Hellwig S. Möglichkeiten und Grenzen des gepulsten Farbstofflasers. *Z Hautkr* 1996;71:96 – 102.
21. Katugampola GA, Rees AM, Lanigan SW. Der Laser in der Behandlung der Psoriasis. *Z. Hautkr* 1995;70:917 – 921.

Copyright (c) 1997-2002 PD Dr. med. Christian Raulin. Alle Rechte vorbehalten.

Fragen, Anregungen und Kritik bitte an den [Webmaster](#).

Letzte Änderung: Montag, 10. Juli 2000

[Webdesign und Pflege by ISD](#)

[Homepage](#)

[Seitenanfang](#)