

ORIGINAL ARTICLE

Combination of short- and long-pulsed mode of electro-optical synergy technology for photoepilation: A retrospective study with short- and long-term follow-up

S Karsai,[†] L Schmitt,[†] C Raulin,^{†*} S Hammes^{*†}[†]Laserklinik Karlsruhe, Karlsruhe, Germany^{*}University of Heidelberg, Department of Dermatology, Heidelberg, Germany^{*}Correspondence: S Hammes. E-mail: info@raulin.de

Abstract

Background The dual-energy technology of ELOS™ showed promising results for photoepilation of dark as well as blond and white hairs; however, only few studies exist on this topic.

Objective To assess the short- and long-term effect of an electro-optical synergy device for photoepilation.

Materials and methods We carried out a retrospective study on 24 patients with unwanted facial hair.

Each area was treated consecutively with two passes using a combined-energy system [intense pulsed light (680–980 nm)/bipolar radiofrequency]. The short-term results were assessed semiquantitatively by three independent dermatologists based on photographs taken before and after treatment; evaluation of long-term results was based on a telephone questionnaire.

Results After a mean of 5.2 treatments and 3.2 months follow-up, 22.2% of the treatment areas showed no/poor clearance, 28.9% moderate, 46.7% good and 2.2% excellent. Similar results were seen in thin and thick hair as well as fair and dark hair.

After a period of 2 years, eight patients were satisfied with the results and did not wish any further treatment. Ten patients continued treatment with an electro-optical synergy device: After an average of 3.6 sessions, 70% of them were satisfied with the results. Five patients ceased treatment because the success did not meet their expectations.

Conclusions Two passes with this combined-energy system are an effective treatment option for the removal of thin, thick, fair and dark hair; however, the system has no significant advantages over other available methods of photoepilation.

Received: 19 February 2008; Accepted 9 June 2008

Keywords

hair removal, lasers, phototherapy, radiofrequency, skin type

Conflicts of interest

None declared

Introduction

The dual-energy technology of ELOS™ (which stands for **electro-optical synergy**) uses synchronous pulses of bipolar radiofrequency current and pulsed visible light delivered within the same pulse. This new approach was recently introduced as a complement to the increasingly diverse variety of non-ablative laser devices on the market. The general idea of this method is to reduce the intensity – and thus, the potential side-effects – of optical energy

by combining it with bipolar radiofrequency (RF), which is supposed to concentrate where the light has selectively heated the target.¹ The main application of this technology is non-ablative resurfacing or rejuvenation of the skin^{2,3} and treating leg veins,^{4,5} but it has also been employed for hair removal.^{6–9}

State-of-the-art systems for light-based removal of unwanted hair are the alexandrite laser (755 nm), Nd:YAG laser (1064 nm) and intense-pulsed light (IPL) devices. Without remarkable differences between systems, these approaches normally provide a reasonable reduction of hair after three to eight treatment sessions in 1- to 2-month intervals.^{9–12} However, the lighter and thinner the hair and the darker the skin, the more difficult it is to

Financial disclosure: None of the authors of the study has financial interests of any kind or is in any way related to the manufacturer, wholesalers or retailers of the device under investigation.

strike a balance between efficacy and tolerability.¹³ The former point is progressively relevant in repeated treatments because the hair that grows back after photoepilation is finer than the original.⁹

Given this background, the combination of a 'melanin-dependent' (IPL) and a 'melanin-independent' (RF) source of energy provided by ELOS™ has the potential to improve the results of photoepilation in fair/white hair and to reduce side-effects occurring in dark skin types.^{1,14}

Apart from wavelength and fluence, the pulse duration is an essential physical factor that influences the effectiveness of photoepilation. It must conform to the diameter of the hair follicle and/or the bulge area. With a follicle size of about 200–300 µm, pulse durations of 10–50 ms are theoretically necessary to destroy the follicle thermally.⁶ Assuming various follicle sizes (terminal hairs vs. vellus hairs), the same pulse duration cannot affect all hairs in the area. The concept of pulse-width dependence of follicle destruction, however, is not undisputed.¹⁵ Therefore, we employed a new approach entailing two successive passes with two different pulse durations.

The study was conducted to contribute to clarifying the following issues:

- Does ELOS™ technology have an effect superior or similar to that of established photoepilation methods?
- Does its effect depend on the thickness and melanin content of the hair?

Materials and methods

Demographic data

Twenty-four patients (23 women, 1 male-to-female transsexual patient) with unwanted hair growth on the face and neck were enrolled in this retrospective study. Their ages ranged from 12 to 76 years (mean 41.1 years). Eleven patients presented Fitzpatrick skin type II and 13 skin type III. Fitzpatrick skin types > III are not represented in this study because of the non-availability of these skin types during the study period. Altogether, 45 areas were treated (21 upper lips, 11 chins, 8 cheeks, 5 necks). The variety in hair colours and hair structures is listed in Table 1. We defined a hair as 'thick' if it was a terminal hair, and as 'thin' if it was a vellus-type fine or downy hair. All patients gave their written consent.

Table 1 Classification of hair types

Hair colour	Hair structure	Absolute number (n)‡	Number in percent (%)
Fair*	Thin	15	31.2
Dark†	Thin	14	29.2
Fair*	Thick	9	18.8
Dark†	Thick	10	20.8

*White and blond.

†Brown and black.

‡The absolute number of different hair types ($n = 48$) differs from the absolute number of treatments areas ($n = 45$) due to the vicinity of different hair types within a treatment area.

Treatment schedule

Each patient in the study underwent a minimum of three treatment sessions with Aurora™ (IPL: 680–980 nm, max. fluence 30 J/cm²; bipolar RF: 1 MHz, max. fluence 20 J/cm³; Syneron Medical Ltd, Israel). The treatment schedule was based on hair biology and predicted hair cycling times; synchronous regrowth was required for treatment repetition, since this indicates that the majority of follicles were in the anagen stage and thus vulnerable to thermal injury. The first three treatments were done at 4- to 6-week intervals. This was an attempt to affect most of the follicles in the area at some point during the anagen phase. After the third session, however, retreatment was done after synchronous regrowth appeared. For this reason, the treatment intervals were extended to about 3 months after the initial period. Follow-up took place after 3 months and 2 years.

Treatment technique

The device under investigation can be operated in the 'short-pulsed mode' (15–22 ms IPL, 150 ms RF) and the 'long-pulsed mode' (100 ms IPL, 200 ms RF). The skin surface is cooled down to 5 °C by means of an integrated contact cooling system.

We carried out two passes each time, using the 'short-pulsed mode' for the first and the 'long-pulsed mode' for the second pass (each time, three pulses). The two passes were applied consecutively, without pauses or cooling in between. We started at the same localization every time. Pulses were placed in an adjacent, minimally overlapping pattern. The IPL energy fluence for the first treatment was between 12 and 20 J/cm² and the RF energy at about 14 J/cm³, depending on the skin type, degree of sun-tan and test pulses adjacent to the study site. The fluence was increased in subsequent treatments depending on the patient's tolerance and the occurrence of side effects. The mean IPL fluence used was 23.7 J/cm²; the average RF fluence was 17.6 J/cm³.

The patients were instructed not to wax, pluck or tweeze 2 weeks before treatment; instead, the treatment areas were shaved 2 days prior to a treatment session.

Assessment of clearance and side effects

Three months after the last treatment, the objective and subjective clearance rates were evaluated. The application of a quantitative assessment method would have had to take place on patient visits. Thus, objective clearance in this retrospective study was assessed based on comparisons between pre- and post-treatment photographs by three independent dermatologists who were not otherwise involved in the study. For both the objective and subjective clearance assessment, each patient's hair reduction was assigned a clearance score as follows: no/poor clearance (0–25%), moderate (26–50%), good (51–75%) or excellent (76–100%). Standardized photos were taken with Canon EOS100 (Canon USA, Inc., Lake Success, NY, USA) using Agfa Ctx100 films (AgfaPhoto GmbH, Leverkusen, Germany).

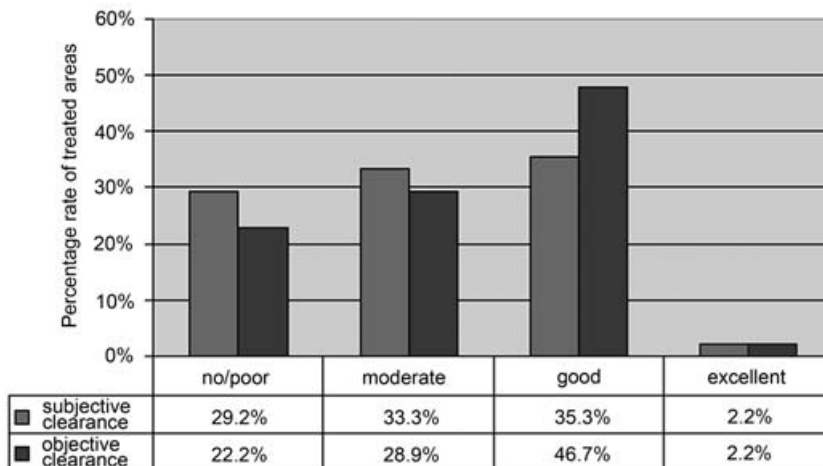


Figure 1 Comparison of subjective and objective clearance ($n = 45$ treatment areas, mean follow-up 3.2 months). No significant difference ($\chi^2 = 2.403$, degree of freedom = 3, $P = 0.493$).

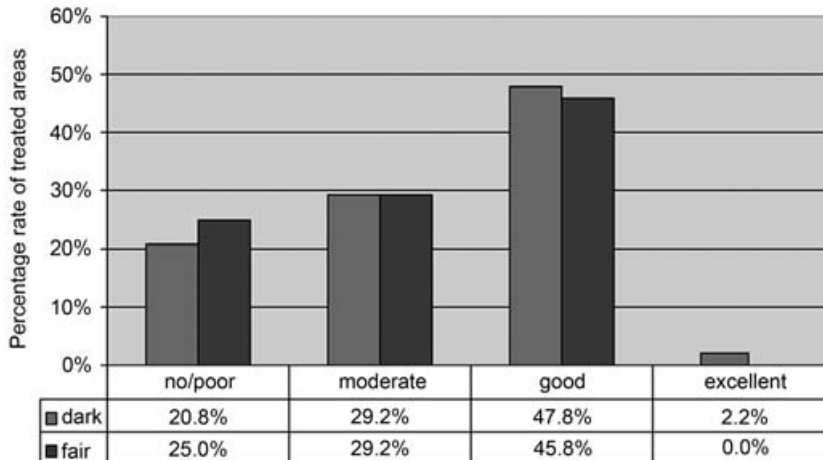


Figure 2 Comparison of objective clearance of dark and fair hair ($n = 45$ treatment areas, mean follow-up 3.2 months). No significant difference ($\chi^2 = 0.273$, degree of freedom = 2, $P = 0.872$).

Concomitant (pain, erythema, swellings) and adverse side-effects (crusting, blistering, hypo-/hyperpigmentation, scarring) were recorded directly and at each follow-up visit.

The 2-year follow-up after the final treatment was carried out as a telephone questionnaire, since many of the study patients had moved or did not want to come in for another follow-up. We asked about subjective satisfaction (yes/no) and further course of treatment.

Statistical evaluation

Statistical evaluation of data was performed with the SPSS package, employing the Mann-Whitney- U -test and χ^2 -test with a significance level of $P < 0.05$.

Results

Patients underwent 3–11 (average 5.2) treatment sessions with an average interval of 4.3 weeks in between sessions. Treated areas included the upper lip ($n = 21$), chin ($n = 11$), cheek ($n = 8$) and

neck ($n = 5$). After a mean follow-up of 3.2 months, 22.2% of the areas had no/poor hair reduction, 28.9% moderate, 46.7% good, and 2.2% were rated as excellent (objective clearance, Fig. 1). There were similar results in fair and dark hair, as well as thin and thick hair (Figs 2 and 3). The amount of hair reduction did not depend on the skin type or area under treatment.

The number of treatments administered in this study depended on therapeutic success; nevertheless, a higher number of sessions was strongly associated with a better final result.

Objective and subjective clearance showed good consistency: The average objective score was lowest in patients who reported no subjective improvement and highest in patients who were satisfied ($P < 0.001$).

Prolonged erythema (1–2 h) was reported for 58.3% of the treated areas, swelling (2–5 days) and a subsequent post-inflammatory hyperpigmentation (2 weeks) occurred in two cases (4.2% of treated areas). Hypopigmentations, blistering or crusting did not occur. The patients tolerated the procedure well without anaesthesia.

Figure 3 Comparison of objective clearance of thin and thick hair ($n = 45$ treatment areas, mean follow-up 3.2 months). No significant difference ($\chi^2 = 0.664$, degree of freedom = 2, $P = 0.717$).

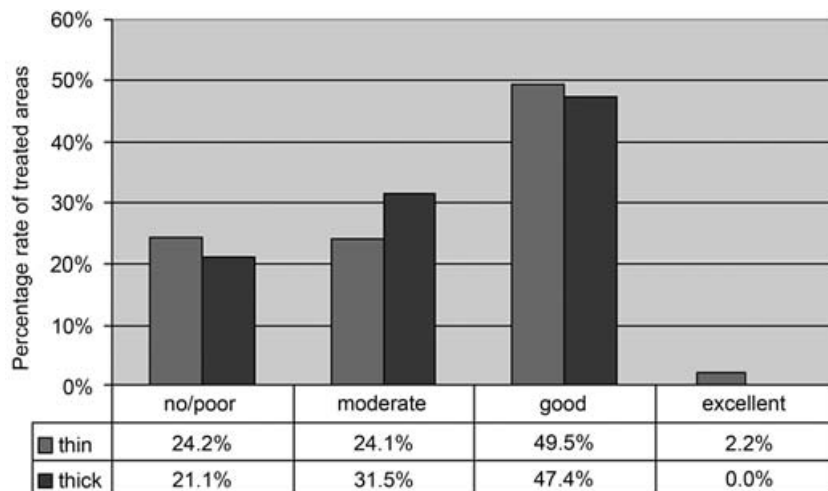


Table 2 Follow-up after 2 years (telephone questionnaire)

(n)*	Patients' comments (telephone questionnaire)
8 patients	Treatment finished, no further treatment
10 patients	Treatment continued with Aurora™: 70% satisfied with the result after an average of 3.6 further sessions
5 patients	Unsatisfactory clearance, further treatment with alexandrite laser, needle epilation

*One patient was lost to follow-up because she moved away.

After 2 years, eight patients who had had no further therapy were satisfied with the achieved results (Table 2). Ten patients continued the therapy with the device under investigation; 70% of these patients were satisfied after an average of 3.6 sessions. Due to unsatisfactory results, five patients were further treated with other methods (alexandrite laser and/or needle epilation); the results, however, were unsatisfactory as well. One patient was lost to long-term follow-up because she moved away.

Discussion

All in all, there are three studies that evaluate the effect and the safety of ELOS™ technology for photoepilation.⁶⁻⁸ In these trials, the number of passes varied (1-3,⁶ up to 4,⁷ not stated⁸), but all three employed pulse durations of 120 ms for IPL and RF, respectively. As for the results of photoepilation in general,¹⁶ however, evidence of the efficacy and safety of the method is meager. The first studies on dual-energy photoepilation were published by working groups associated with Sadick and Goldberg.⁶⁻⁸ Two of these studies specifically addressed the removal of blond and white hair,^{6,7} concordantly reporting a reduction by about 40-50% after repeated treatment sessions. The aforementioned studies employed the following treatment parameters:

- Goldberg *et al.*:⁶ Two treatments at an interval of 4 to 6 weeks, RF energy 20 J/cm³, optical fluence 24-30 J/cm², short pulse profile, 1-3 passes with erythema as a desired endpoint.
- Sadick and Laughlin:⁷ Four treatments within 9-12 months, RF energy 20 J/cm³, optical fluence 24-30 J/cm², maximum of 4 passes with erythema lasting for 'more than a few minutes' as an endpoint.
- Sadick and Shaoul:⁸ Four treatments within 9-12 months at 8- to 12-week intervals, RF energy 10-20 J/cm³, optical fluence 15-26 J/cm², number of passes not stated.

Goldberg *et al.* compared ELOS™ technology with and without topical aminolevulinic acid for terminal and vellus non-pigmented hairs.⁶ Six months after the last treatment (two sessions), 35% of the terminal and none of the vellus hairs had cleared. The clearance of the terminal hairs increased to 48% after applying aminolevulinic acid, while the clearance of the vellus hairs remained unchanged. There were no serious side effects even when treating patients with Fitzpatrick skin type IV.

Sadick and Laughlin treated only patients with blond and white hair and reported a 52% clearance for blond and 44% clearance for white hair (6 months follow-up, 4 treatments).⁷ In another study (4 treatments), an average clearance rate of 75% was reported, whereas the percentage of patients with blond, white and red hair was underrepresented (27.5%).⁸ With blond and red hair, respectively, a clearance of 60% was achieved, whereas the clearance was 40% with white hair. In both studies, minimal side-effects were reported despite the inclusion of skin type V.

Due to methodological issues, the direct comparison of the quoted studies is problematic, but a clearance of roughly 50% of all terminal hair and 30% of blond/white hair may be assumed according to their results.

In contrast to the aforementioned studies, we treated each area applying two passes, the first in the short-pulsed mode (15-22 ms IPL, 150 ms RF), the second in the long-pulsed mode (100 ms IPL,

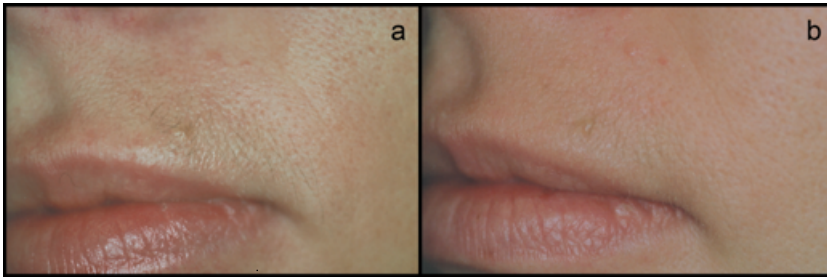


Figure 4 Clinical appearance of the upper lip before (a) and after (b) 5 treatment sessions (76–100% clearance).

200 ms RF). The differences in pulse durations between the studies by Goldberg⁶ and Sadick^{7,8} and our trial are a consequence of the manufacturer's optimization and further development of the device features. Additionally, we differentiated not only between hair colours, but also between hair structures (thick vs. thin), since the hair structure is a major determining factor in the success or failure of epilation treatments.

Altogether, we treated 38 areas (79.2%) with the – particularly challenging – combination of fair, thick and thin hairs in close vicinity, and only 10 areas (20.8%) with generally well-responding hairs (i.e. dark and thick) (Table 1). In spite of the high proportion of 'problem hairs,' the total clearance was assessed as 'moderate' or 'good' in 75.6% (objective assessment) and 68.6% (subjective assessment) of cases (Fig. 1). Interestingly, we did not observe a significant difference between the epilation results with dark vs. fair hair nor with thick vs. thin hair, a finding in contrast with the results of other photoepilation methods^{9–12} as well as previous studies on ELOS[™].^{6–8} Thus, the application of different pulse durations might have a more pronounced effect on 'problem hairs,' although this can only be assumed owing to the lack of a control group.

None of the studies published to date have included such a high number of patients with fair and thin hair as the present one, so the absence of 'excellent' clearances must be considered in light of this challenging background. Still, in comparison with other methods of photoepilation,^{9–12} the advantages of ELOS[™] are rather moderate, and the overall benefit is not convincing enough yet to warrant a general recommendation.

It must be emphasized that, in spite of the application of two passes, the range of side effects was very small. We observed no crusting, blistering or scarring. The two cases of prolonged swelling (2–5 days) with post-inflammatory hyperpigmentation (2 weeks) were probably caused by an insufficient placement of the electrode rails on the area under treatment. At this point, it is important to mention that, during treatment, the electrodes must at all times lie directly on the skin in order to prevent unnecessary skin irritations.

As mentioned by Sadick and Makino, we also observed that ELOS[™] technology is associated with slower thinning and slower loss of hair compared with other light and laser systems.¹⁴ For this reason, the patients initially often underrate its efficacy. As with

numerous other published studies on photoepilation, the clearance rate in our study increased considerably with the number of treatment sessions. It has to be stressed, however, that success is limited since only 2.2% of the treated areas showed almost complete clearance (Fig. 4).

In conclusion, the short- and long-term results indicate that the application of two passes of ELOS[™] technology may be an alternative to other kinds of photoepilation, especially as far as the removal of mixed (thin and thick, fair and dark) hair is concerned. We were the first – and so far the only ones – to evaluate the application of two successive passes (short- and long-pulsed mode) per treatment session, which might explain the better results in 'problem hairs' as compared to previously published studies on ELOS[™].^{6–8} However, owing to methodological limitations, the descriptive nature of the present study and the relative sparseness of published results, recommendations for the practical application of ELOS[™] photoepilation would be premature. Controlled studies that compare the method with other light sources as well as different kinds of ELOS[™] technology with one another are required to prove efficacy and safety and to establish standardized treatment parameters.

Finally, we have performed an extensive literature review; however, the question of possible RF selectivity with a change of the electrical properties by preceding optical energy for targets other than melanin as suggested by Sadick¹ cannot be answered conclusively at the moment. His own clinical trials fail to underline it in convincing fashion.

References

- 1 Sadick NS. Combination radiofrequency and light energies: electro-optical synergy technology in esthetic medicine. *Dermatol Surg* 2005; **31**: 1211–1217.
- 2 Kulick M. Evaluation of a combined laser-radio frequency device (Polaris WR) for the nonablative treatment of facial wrinkles. *J Cosmet Laser Ther* 2005; **7**: 87–92.
- 3 Hammes S, Greve B, Raulin C. Electro-optical synergy (ELOS) technology for nonablative skin rejuvenation: a preliminary prospective study. *J Eur Acad Dermatol Venereol* 2006; **20**: 1070–1075.
- 4 Chess C. Prospective study on combination diode laser and radiofrequency energies (ELOS) for the treatment of leg veins. *J Cosmet Laser Ther* 2004; **6**: 86–90.
- 5 Sadick NS, Trelles MA. A clinical, histological, and computer-based assessment of the Polaris LV, combination diode, and radiofrequency system, for leg vein treatment. *Lasers Surg Med* 2005; **36**: 98–104.

- 6 Goldberg DJ, Marmur ES, Hussain M. Treatment of terminal and vellus non-pigmented hairs with an optical/bipolar radiofrequency energy source – with and without pre-treatment using topical aminolevulinic acid. *J Cosmet Laser Ther* 2005; 7: 25–28.
- 7 Sadick NS, Laughlin SA. Effective epilation of white and blond hair using combined radiofrequency and optical energy. *J Cosmet Laser Ther* 2004; 6: 27–31.
- 8 Sadick NS, Shaoul J. Hair removal using a combination of conducted radiofrequency and optical energies – an 18-month follow-up. *J Cosmet Laser Ther* 2004; 6: 21–26.
- 9 Gansel RW Photoepilation: State-of-the-art. *Hautarzt* 2008; 59: 124–130.
- 10 Drosner M, Adatto M. European society for laser dermatology. Photo-epilation: guidelines for care from the European Society for Laser Dermatology (ESLD). *J Cosmet Laser Ther* 2005; 7: 33–38.
- 11 Amin SP, Goldberg DJ. Clinical comparison of four hair removal lasers and light sources. *J Cosmet Laser Ther* 2006; 8: 65–68.
- 12 Nouri K, Vejjabhinanta V, Patel SS, Singh A. Photoepilation: a growing trend in laser-assisted cosmetic dermatology. *J Cosmet Dermatol* 2008; 7: 61–67.
- 13 Breadon JY, Barnes CA. Comparison of adverse events of laser and light-assisted hair removal systems in skin types IV–VI. *J Drugs Dermatol* 2007; 6: 40–46.
- 14 Sadick NS, Makino Y. Selective electro-thermolysis in aesthetic medicine: a review. *Lasers Surg Med* 2004; 34: 91–97.
- 15 Altshuler GB, Anderson RR, Manstein D, Zenie HH, Smirnov MZ. Extended theory of selective photothermolysis. *Lasers Surg Med* 2001; 29: 416–432.
- 16 Haedersdal M, Gøtzsche PC. Laser and photoepilation for unwanted hair growth. *Cochrane Database Syst Rev* 2006; 4: CD004684.

This document is a scanned copy of a printed document. No warranty is given about the accuracy of the copy. Users should refer to the original published version of the material.